

Research Article

A Comparison of Visual Outcomes of Deep Anterior Lamellar Keratoplasty versus Penetrating Keratoplasty in Patients with Keratoconus

Shaam Mahasneh^{1,2#}, Joanna S. Saade^{1,2,3#}, Bachir Abiad^{1,2} and H Dwight Cavanagh^{1,2*}

¹Department of Ophthalmology, University of Texas Southwestern Medical Center, Dallas, USA

²Department of Ophthalmology, Parkland Memorial Hospital, Dallas, USA

³Department of Ophthalmology, American University of Beirut Medical Center, Beirut, Lebanon

- Contributed Equally

Abstract

Background/Objective: Deep Anterior Lamellar Keratoplasty (DALK) was found to be superior to Penetrating Keratoplasty (PKP) in terms of reduced risk of endothelial rejection, lower loss of endothelial cell density, and lower risk of ruptured globe injury after trauma. The purpose of this study is to compare in details the visual and surgical outcomes of these two procedures and the need for Rigid Gas Permeable (RGP) lens correction to achieve Best Corrected Visual Acuity (BCVA) following both procedures in advanced Keratoconus (KCN) cases.

Methods: Retrospective chart review of 61 eyes with KCN that underwent PKP or DALK from July 2011 to January 2017. Outcome measures noted were: Best Corrected Visual Acuity (BCVA), Uncor-

*Corresponding author: H Dwight Cavanagh, Department of Ophthalmology, University of Texas Southwestern Medical Center, 5323 Harry Hines Blvd, Dallas, TX 75390-9057, USA, Tel: +1 2146483770; Fax: +1 2146489061; E-mail: Dwight.Cavanagh@UTSouthwestern.edu

Citation: Mahasneh S, Saade JS, Abiad B, Cavanagh HD (2018) A Comparison of Visual Outcomes of Deep Anterior Lamellar Keratoplasty versus Penetrating Keratoplasty in Patients with Keratoconus. J Ophthalmic Clin Res 4: 045.

Received: July 25, 2018; **Accepted:** August 20, 2018; **Published:** August 31, 2018

Copyright: © 2018 Mahasneh S, et al. This is an open-access article distributed under the terms of the Creative Commons Attribution License, which permits unrestricted use, distribution, and reproduction in any medium, provided the original author and source are credited.

rected Visual Acuity (UCVA), post-operative refraction, topographic astigmatism, use of Rigid Gas Permeable (RGP) lenses, and complications.

Results: Twenty six eyes were in the DALK group (42.6%), thirty five in the PKP group (57.4%). UCVA for the DALK group was 0.65 logMAR (SD=0.32) and for the PKP group 0.84 logMAR (SD=0.37) (p-value 0.043). BCVA for the DALK group was 0.205 logMAR (SD=0.16) and for the PKP group was 0.316 (SD=0.24) (p-value 0.05). The DALK group was more likely to have BCVA better or equal to 20/40 (23/26, 88.4%) than the PKP group (20/35, 57.1%), p-value 0.011. Manifest astigmatism in the DALK group was 3.69 D (SD=2.80) and in the PKP group was 3.66 D (SD=2.65), p-value 0.81. Topographic astigmatism in the DALK group was 4.13 D (SD=2.70), in the PKP group was 5.71 D (SD=4.82), p-value 0.22. Forty percent in the PKP group required post-operative RGP lens correction versus 19.2% in the DALK group, (p=0.08). There were 26.9% (7/26) complications in the DALK group versus 54.3% (19/35) in the PKP group (p-value 0.04).

Conclusion: DALK appears to provide a more favorable outcome for the surgical management of keratoconus with lower complications, including post-operative rejection rates. Although not statistically significant, DALK appears to result in better visual outcomes and lower dependence on RGP lens wear.

Keywords: Deep Anterior Lamellar Keratoplasty (DALK); Keratoconus (KCN); Penetrating Keratoplasty (PKP); Rigid Gas Permeable (RGP)

Introduction

Keratoconus (KCN) is a bilateral non-inflammatory, degenerative corneal ectasia with central and paracentral thinning [1]. A clear definition was established by the Global Consensus on keratoconus and ectatic disease in 2015 which included: "abnormal posterior ectasia, abnormal corneal thickness distribution and clinical non inflammatory corneal thinning" [1].

In advanced stages, disease progression in KCN leads to significant loss of the quality of vision due to corneal irregularity. Progressive protrusion can result in spontaneous breaks in Descemet's Membrane (DM) causing acute corneal hydrops which can lead to corneal scarring [2].

The pathogenesis is not fully understood, although there have been some conditions associated with KCN such as atopy, Down's syndrome, and eye-rubbing [3-6]. The reported incidence ranges from 1.3-25 per 100,000 per year across different populations, and a prevalence of 8.8-229 per 100,000 depending on the geographic location of the population being studied [7]. Recently, new developments have been established to improve the visual prognosis in patients with KCN using new contact lens designs in Rigid Gas Permeable Lenses (RGP CL) and piggy-back lens systems and Intracorneal Ring Segments (ICRS) [2]. Implantation of the intracorneal rings has been shown to alter the keratometry readings and improve vision [8,9].

However, the most important new therapeutic intervention that has been shown to alter the natural course of the disease is corneal

cross-linking. Cross-linking was recently approved by the Food and Drug Administration in April, 2016 for progressive keratoconus and post-refractive corneal ectasia [10]. It is shown to halt the progression of the disease and stabilize or improve vision by studies investigating short and long term outcomes [11,12]. Recently, Hashemi et al., reported that over five years, cross linking stabilized Uncorrected Visual Acuity (UCVA), refraction, anterior and posterior corneal elevation, corneal power and thickness, and ultimately long term best corrected visual acuity [13]. In very advanced KCN cases, the diseased cornea may be an unsuitable candidate for these rehabilitative, new options and corneal transplantation techniques may need to be considered.

Penetrating Keratoplasty (PKP) is the transplantation of a full thickness corneal graft. It was first successfully performed by Eduard Zirm in 1905 [14]. Over the next century, surgeons began to perform PKPs using Zirm's technique, which became the standard of care in the transplantation community [15]. Anton Elschnig performed the first anterior lamellar keratoplasty in 1914 for a case of interstitial keratitis. However, it was not until the 1950's that Charles Tillet performed the Endothelial Keratoplasty (EK) for a case of corneal edema [15]. Given the problems that arose with lamellar keratoplasty such as interface haze and scarring, the procedure was not frequently utilized. In the 1990's the possibility of lamellar keratoplasty was reinvestigated and reintroduced to clinical practice [16].

Deep Anterior Lamellar Keratoplasty (DALK), a form of anterior lamellar keratoplasty, involves the removal of the central corneal stroma leaving behind the host's endothelium and DM. It is beneficial in patients with abnormal stroma and in the presence of normal endothelium, particularly in the second eye of patients with a history of endothelial rejection following PKP in the first eye. DALK is a technically more challenging procedure than PKP with the rate limiting step being successful bearing of the DM. This dissection adds an element of unreliability to the procedure. The most common intra-operative complication reported is DM perforation, which occurs in 11.7% of attempted DALK procedures [15]. Numerous techniques have been described in the literature to avoid this complication such as the Melles manual dissection, viscoelastic dissection and the Anwar big bubble technique [16-18]. The advantages of DALK over PKP based on the literature are reduced risk of endothelial rejection, lower loss of endothelial cell density, lower risk of ruptured globe injury after trauma, a potential shorter length of time of steroid use and shorter time to suture removal [15].

The purpose of this study is to compare the visual and surgical outcomes of these two surgical procedures in patients with advanced keratoconus and to compare the need for Rigid Gas Permeable (RGP) lens correction to achieve BCVA following both procedures.

Methods and Outcome Measures

A retrospective comparative chart review of 61 eyes from 61 patients with keratoconus who underwent PKP or DALK at the University of Texas Southwestern University Hospital and Parkland Memorial Hospital from July 2011 to January 2017 was done. Cases were identified through a search of ICD-9 and ICD-10 for Keratoconus. From that search, a second query was performed for Current Procedural Terminology (CPT) codes within the UTSW departmental billing database for PKP and DALK. Charts of all patients were reviewed and compiled into a dataset. This study was approved by the

Institutional Review Board at the University of Texas Southwestern Medical Center, and complied with the declaration of Helsinki.

Inclusion criteria included patients with 12 months of follow-up postoperatively. DALK successfully completed were included in the DALK group, if DALK proved infeasible intraoperatively, it was included as PKP. There were no other complications in either group. Exclusion criteria included any other pre-existing ocular pathology that would affect the best corrected visual acuity such as glaucoma, pseudophakia, aphakia and all DALK cases that needed to convert to PKP intraoperatively.

All DALK procedures were performed using the Anwar big bubble technique (100%) and the graft subsequently sutured using 16 10-0 nylon interrupted sutures. PKP was performed in the standard established technique, using running or interrupted sutures. All patients from the PKP group were instructed to use prednisolone acetate 1% on an hourly basis while awake for one month, followed by six times daily for two more months, while patients from the DALK group were instructed to use prednisolone acetate 1% on an hourly basis while awake for a two-week period, followed by six times daily for six weeks. A slow taper over a minimum of six months followed for patients from both groups according to the clinical picture. All patients had all sutures in place at time of post-operative evaluation.

Data collection points included age at the time of surgery, sex, and eye laterality. The following reported exam findings, recorded at 12 months post operatively, were included: Uncorrected Visual Acuity (UCVA), Best Corrected Visual Acuity (BCVA) with or without a need for RGP, topographic astigmatism, post-operative astigmatism on manifest refraction, and Rigid Gas Permeable (RGP) lens wear. UCVA and BCVA were compared after converting the values to logMAR values. Other outcome measures investigated were secondary high intra-ocular pressure and rejection rates (epithelial, stromal or endothelial). Pre-operative visual acuity values were extremely desperate due to differences in RGP lens wear prior to surgery. All cases included had VA of 20/80 or worse.

For statistical analysis of quantitative data, the unpaired t-test was used. For analysis of rejection rates and complication rates in both groups, a fisher's exact test was used. Statistical significance was defined with $p < 0.05$.

Results

Sixty-one eyes met the inclusion criteria including 26 eyes in the DALK group (42.6%) and 35 eyes in the PKP group (57.4%). The patient demographics are reported in table 1. No patients had or developed infectious keratitis. The DALK patients achieved statistically significant better UCVA as well as mean Best Corrected Visual Acuity (BCVA) than the PKP group, p -value 0.04 and p -value 0.03 respectively. The DALK group was also more likely to have BCVA \leq 20/40 than the PKP group p -value 0.011 (Table 2A). Pre-operative VA was 20/80 or worse in all eyes included in the study. Zero percent of eyes in the DALK group had post-operative BCVA of 20/80 or worse versus 14.3% of eyes in the PKP group had post-operative BCVA of 20/80 or worse. The astigmatism evaluated in both groups was astigmatism obtained on manifest refraction and topographic astigmatism. Neither data point was found to be statistically significant between both groups (Table 2B). Far more eyes in the PKP group required

Rigid Gas Permeable (RGP) contact lenses to improve vision compared with the DALK group, although this was not statistically significant ($p=0.08$) (Figures 1A & 1B).

| | DALK | PKP |
|------------------------|------|------|
| Number of eyes | 26 | 35 |
| Ratio of female : Male | 1.17 | 1.92 |
| Mean age | 35.1 | 37 |

Table 1: Demographics data.

| | DALK | | PKP | | P-value |
|---------------------------------------|------|--------------------|------|--------------------|---------|
| | Mean | Standard Deviation | Mean | Standard Deviation | |
| Uncorrected visual acuity (logMAR) | 0.65 | 0.32 | 0.84 | 0.37 | 0.04 |
| Best corrected visual acuity (logMAR) | 0.21 | 0.16 | 0.32 | 0.24 | 0.03 |
| Manifest astigmatism (Diopters) | 3.69 | 2.8 | 3.66 | 2.65 | 0.81 |
| Topographic astigmatism (Diopters) | 4.13 | 2.7 | 5.71 | 4.82 | 0.19 |

Table 2A: Comparison between groups of UCVA, BCVA, Manifest and Topographic astigmatism at post-operative month 12.

| | Number and Percentage in DALK group | Number and Percentage in PKP group | P-Value |
|---|-------------------------------------|------------------------------------|---------|
| Rigid gas permeable use | 5/26 (19.2%) | 14/35 (40%) | 0.08 |
| Complication rate | 7/26 (26.9%) | 19/35 (54.3%) | 0.04 |
| Best corrected visual acuity \leq 20/40 | 23/26 (88.4%) | 20/35 (57.1%) | 0.01 |

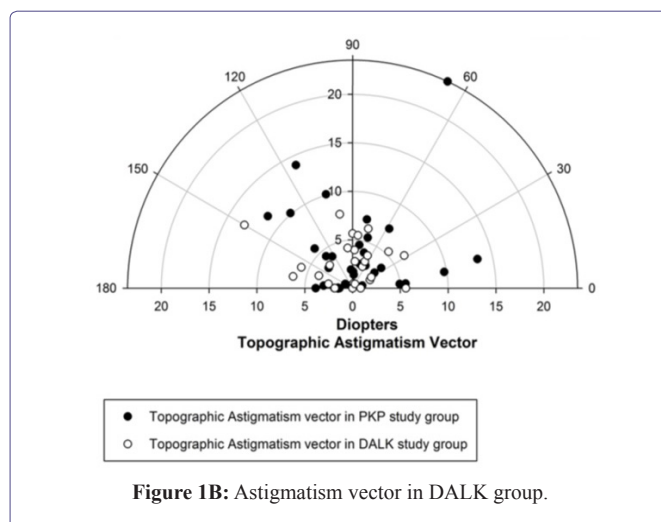
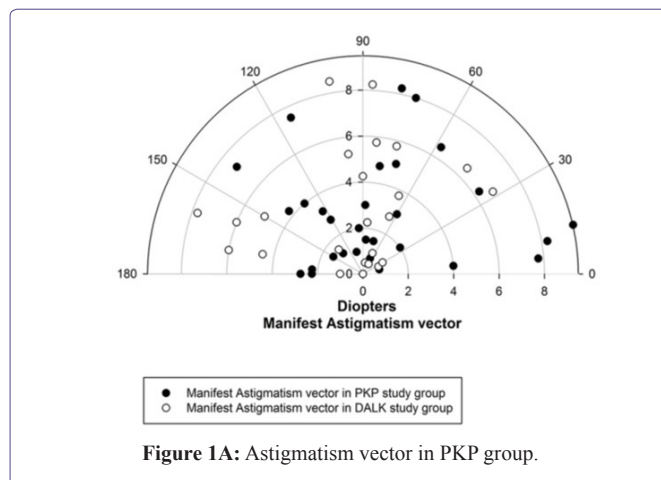
Table 2B: Comparison between groups of the RGP use, complication rate and BCVA \leq 20/40.

Seven patients (26.9%) in the DALK group and 19 patients (54.3%) in the PKP group had complications (p -value 0.04). Complication in both groups included development of secondary glaucoma requiring medical or surgical therapy, cataracts or dehiscence of the graft requiring re-suturing, and graft rejection (Table 3).

| | DALK | PKP | p-value (Fisher's exact test) |
|----------------------------------|-----------------|----------------------|-------------------------------|
| Rejection | 2 (all stromal) | 10 (all endothelial) | 0.0547 |
| Secondary glaucoma | 3 | 12 | 0.0696 |
| Cataracts | 1 | 3 | 0.6294 |
| Dehiscence requiring re-suturing | 2 | 2 | 1 |

Table 3: Complications.

Two patients (8.3%) in the DALK group had stromal rejection and ten patients (28.5%) in the PKP group had endothelial rejection (Table 3).



Discussion

In this study, DALK was found to provide better UCVA and BCVA than PKP; specifically, the DALK group was more likely to have BCVA \leq 20/40 (LogMar+0.30). When compared with pre-operative VA, all DALK eyes showed an improvement in post-operative BCVA where as 14.3% of PKP eyes did not show an improvement in post-operative VA further emphasizing the better visual outcomes with DALK. Most of the published meta-analysis studies show comparable long term visual outcome results between the two groups [19,20], with a few studies showing better visual outcomes in the PKP group [15,21]. However there have been studies that have shown better visual outcomes in the DALK group compared to the PKP group [22]. Visual outcome results can be affected by various factors such as suture technique, the surgeon's experience, and the ability to successfully bare the DM [19]. A recent Cochrane review comparing both methods found insufficient evidence as to which technique gave better overall visual results. There were no differences between both surgeries in regards to spherical equivalence and keratometric astigmatism but refractive astigmatism was better with DALK [23].

Most of the DALK procedures in this study were performed by cornea fellows in training (23/26, 88.4%) highlighting that this procedure can be successful in the hands of less experienced surgeons.

Asena et al., reported that 17% of the eyes that underwent PKP in their series needed RGP CL fitting [24]. Another large study reported that 47% of eyes required RGP CL fitting after PKP, on an average of 8.5 months post-surgery [25]. In another study, 60% wore either bispberic or hard contact lens post PKP [26]. Prazeres et al., looked at 38 eyes post PKP and 1 eye post DALK and reported that CL fitting was done as early as 9 months but that the average time was 50.9 months, may be due to delayed referral by physicians. In that series, thirty eight percent of eyes required an RGP CL [27].

A novel finding in this study was that fewer patients in the DALK group (19.2%) required post-operative RGP lenses to improve BCVA compared to the PKP group (40%). This may be attributed to the better UCVA results post-operatively and highlights DALK as a more favorable surgical option for visual rehabilitation especially for those who grew RGP lens intolerant during the course of their disease; however, the rate of RGP use in the PKP versus the DALK group, although higher, did not meet statistical significance. We hypothesize that this could be attributed to the comparable astigmatism values in both groups. The astigmatism was 3-4 D in both groups, similar to other studies in the literature [15]. One systemic review looking at 965 eyes that underwent DALK and 2402 eyes that underwent PKP, found that patients undergoing DALK had less astigmatism as compared to PKP, but PKP had better best corrected and uncorrected visual outcomes at 6 months [21].

In agreement with the previously published studies, the PKP group had a statistically significant higher post-operative complication rate than the DALK group [15,19,23]. In the PKP group, out of the 19 eyes with complications, three eyes required cataract surgery, twelve eyes with secondary glaucoma required medical and/or surgical therapy, ten eyes were treated for rejection, and two eyes with dehiscence necessitated suturing. In the DALK group, out of the seven eyes with complications, two eyes were treated for stromal graft rejection, three eyes needed drops for secondary glaucoma, one eye required cataract surgery, and two eyes required re-suturing, one due to dehiscence and the other due to Descemet's Membrane detachment with a double chamber requiring re-bubbling. The complication rates in this paper are higher than the average reported in the literature. This can be attributed in part to the largely indigent, non-compliant nature of the patient population included in this study. Moreover, all of the surgeries were performed at a teaching institution by surgeons with variable levels of experience.

Moreover, with regards to the complication rates in both groups, the PKP group had a higher rate of rejection than the DALK group. It can be explained by the advantages that the DALK procedure has to offer [15,22]. Firstly, the DALK procedure allows the native endothelium to remain intact hence removing the element of immune rejection of donor corneal endothelium. Secondly, as evidenced by numerous large meta-analyses, the rate of endothelial cell density loss is much higher in PKP eyes [28,29]. This is thought to be due to cell migration, instrumental manipulation, trauma to the tissue during surgery and a biphasic postoperative accelerated loss. Whether the accelerated loss of endothelial cells post-PKP is a subclinical immune endothelial rejection or a result of the other causes discussed, it has yet to be investigated further [15,30-32].

The rejection rate in this study is higher in the PKP group than in the DALK group which is in agreement with the literature. Moreover, the rejection rate in the DALK group is lower than what has been cited in recent literature. Gonzalez et al., showed an overall 14% rejection rate in DALK patients over an 18 month period with a 7-week median of postoperative steroid therapy. Thus, their conclusion was a recommendation of postoperative steroid therapy for longer than 7 weeks. Our study had postoperative steroid therapy for a minimum of six months and an 8.3% stromal rejection rate. Our results are in support of the findings of Gonzalez et al., and a longer course of postoperative steroid therapy is recommended to ensure lower rejection rates.

Extended steroid therapy carries inherent risks which include accelerated cataract formation, elevated intraocular pressure levels that may necessitate glaucoma medications or filtration surgery, ultimately driving the complication rates even higher. Thus clinical judgment must be exercised when determining the appropriate length of steroid therapy and further investigation is needed to establish a safe postoperative regimen.

This study presents the usual limitations that come with a retrospective analysis. Endothelial cell density was not available in this study which would have allowed better analysis over time and should be included in future studies. Moreover, DALK is a rarely performed procedure, which limited the number of eyes in each group and ultimately the power of the study. The rate of conversion from DALK to PKP, which reflects DALK's most common intraoperative complication, was not included. Future studies should include larger groups to confirm the results obtained and further examine at the lower need for post-surgical RGP lenses in eyes that underwent DALK.

In conclusion, this study showed that, despite its steep learning curve, DALK appears more favorable for the surgical management of keratoconus with a lower post-operative complication rate, including rejection rates. Although not statistically significant, it allows better visual outcomes, creating a lesser need for the use of post-surgical RGP lenses to provide BCVA.

Conflict of Interest

There are no conflicts of interest to disclose.

Funding

This project was supported in part by an unrestricted grant from the Research to Prevent Blindness Inc. NY, and by NIH core grant P30EY020799.

References

1. Gomes JA, Tan D, Rapuano CJ, Belin MW, Ambrósio R Jr, et al. (2015) Global consensus on keratoconus and ectatic diseases. *Cornea* 34: 359-369.
2. Parker JS, van Dijk K, Melles GR (2015) Treatment options for advanced keratoconus: A review. *Surv Ophthalmol* 60: 459-480.
3. Weed KH, MacEwen CJ, Giles T, Low J, McGhee CN (2008) The Dundee University Scottish Keratoconus study: demographics, corneal signs, associated diseases, and eye rubbing. *Eye (Lond)* 22: 534-541.
4. Bawazeer A, Hodge W, Lorimer B (2000) Atopy and keratoconus: a multivariate analysis. *Br J Ophthalmol* 84: 834-836.

5. Wagner H, Barr JT, Zadnik K (2007) Collaborative Longitudinal Evaluation of Keratoconus (CLEK) Study: methods and findings to date. *Cont Lens Anterior Eye* 30: 223-232.
6. Haugen OH (1992) Keratoconus in the mentally retarded. *Acta Ophthalmol (Copenh)* 70: 111-114.
7. Liu H, Chen Y, Wang P, Li B, Wang W, et al. (2015) Efficacy and safety of deep anterior lamellar keratoplasty vs. penetrating keratoplasty for keratoconus: a meta-analysis. *PLoS One* 10: 0113332.
8. Lyra JM, Lyra D, Ribeiro G, Torquetti L, Ferrara P, et al. (2017) Tomographic Findings After Implantation of Ferrara Intrastromal Corneal Ring Segments in Keratoconus. *J Refract Surg* 33: 110-115.
9. Torquetti L, Ferrara G, Almeida F, Cunha L, Araujo LP, et al. (2014) Intrastromal corneal ring segments implantation in patients with keratoconus: 10-year follow-up. *J Refract Surg* 30: 22-26.
10. Food and Drug Administration (2018) Approved Drug Products with Therapeutic Equivalence Evaluations (38thedn). Food and Drug Administration, Silver Spring, Maryland, USA.
11. O'Brart DP, Patel P, Lascaratos G, Wang VK, Tam C, et al. (2015) Corneal Cross-linking to Halt the Progression of Keratoconus and Corneal Ectasia: Seven-Year Follow-up. *Am J Ophthalmol* 160: 1154-1163.
12. Raiskup F, Theuring A, Pillunat LE, Spoerl E (2015) Corneal collagen crosslinking with riboflavin and ultraviolet-A light in progressive keratoconus: ten-year results. *J Cataract Refract Surg* 41: 41-46.
13. Hashemi H, Seyedian MA, Miraftab M, Fotouhi A, Asgari S (2013) Corneal collagen cross-linking with riboflavin and ultraviolet a irradiation for keratoconus: long-term results. *Ophthalmology* 120: 1515-1520.
14. Zirm EK (1989) Eine erfolgreiche totale Keratoplastik (A successful total keratoplasty). 1906. *Refract Corneal Surg* 5: 258-261.
15. Reinhart WJ, Musch DC, Jacobs DS, Lee WB, Kaufman SC, et al. (2011) Deep anterior lamellar keratoplasty as an alternative to penetrating keratoplasty a report by the american academy of ophthalmology. *Ophthalmology* 118: 209-218.
16. Sugita J, Kondo J (1997) Deep lamellar keratoplasty with complete removal of pathological stroma for vision improvement. *Br J Ophthalmol* 81: 184-188.
17. van Dooren BT, Mulder PG, Nieuwendaal CP, Beekhuis WH, Melles GR (2004) Endothelial cell density after deep anterior lamellar keratoplasty (Melles technique). *Am J Ophthalmol* 137: 397-400.
18. Anwar M, Teichmann KD (2002) Big-bubble technique to bare Descemet's membrane in anterior lamellar keratoplasty. *J Cataract Refract Surg* 28: 398-403.
19. MacIntyre R, Chow SP, Chan E, Poon A (2014) Long-term outcomes of deep anterior lamellar keratoplasty versus penetrating keratoplasty in Australian keratoconus patients. *Cornea* 33: 6-9.
20. Yüksel B, Kandemir B, Uzunel UD, Çelik O, Ceylan S, et al. (2017) Comparison of visual and topographic outcomes of deep-anterior lamellar keratoplasty and penetrating keratoplasty in keratoconus. *Int J Ophthalmol* 10: 385-390.
21. Henein C, Nanavaty MA (2017) Systematic review comparing penetrating keratoplasty and deep anterior lamellar keratoplasty for management of keratoconus. *Cont Lens Anterior Eye* 40: 3-14.
22. Trimarchi F, Poppi E, Klersy C, Piacentini C (2001) Deep Lamellar Keratoplasty. *Ophthalmologica* 215: 389-393.
23. Keane M, Coster D, Ziaei M, Williams K (2014) Deep anterior lamellar keratoplasty versus penetrating keratoplasty for treating keratoconus. *Cochrane Database Syst Rev* 22: CD009700.
24. Asena L, Altınörs DD (2016) Visual Rehabilitation After Penetrating Keratoplasty. *Exp Clin Transplant* 14: 130-134.
25. Geerards AJ, Vreugdenhil W, Khazen A (2006) Incidence of rigid gas-permeable contact lens wear after keratoplasty for keratoconus. *Eye Contact Lens* 32: 207-210.
26. Smiddy WE, Hamburg TR, Kracher GP, Stark WJ (1988) Keratoconus. Contact lens or keratoplasty? *Ophthalmology* 95: 487-492.
27. Prazeres S, Malet F, Colin J (2008) Contact lens fitting after keratoplasty for keratoconus. *J Fr Ophthalmol* 31: 849-854.
28. Borderie VM, Sandali O, Bullet J, Gaujoux T, Touzeau O, et al. (2012) Long-term results of deep anterior lamellar versus penetrating keratoplasty. *Ophthalmology* 119: 249-255.
29. Kubaloglu A, Sari ES, Unal M, Koytak A, Kurnaz E, et al. (2011) Long-term results of deep anterior lamellar keratoplasty for the treatment of keratoconus. *Am J Ophthalmol* 151: 760-767.
30. Reinhard T, Bohringer D, Hüschen D, Sundmacher R (2002) [Chronic endothelial cell loss of the graft after penetrating keratoplasty: influence of endothelial cell migration from graft to host]. *Klin Monatsbl Augenheilkd* 219: 410-416.
31. Bourne WM (2001) Cellular changes in transplanted human corneas. *Cornea* 20: 560-569.
32. Bohringer D, Reinhard T, Godehardt E, Sundmacher R (2001) [Regression analysis of idiopathic endothelial cell loss after perforating normal risk keratoplasty: basic principles for long-term analysis of endothelial risk factors in a retrospective clinical study]. *Klin Monatsbl Augenheilkd* 218: 412-417.



Addiction & Addictive Disorders
Advances in Industrial Biotechnology
Advances in Microbiology Research
Agronomy and Agricultural Science
AIDS Clinical Research & STDs
Alcoholism, Drug Abuse & Substance Dependence
Allergy Disorders and Therapy
Alternative, Complementary & Integrative Medicine
Alzheimer's & Neurodegenerative Diseases
Anesthesia & Clinical care
Angiology & Vascular Surgery
Animal Research and Veterinary Science
Aquaculture & Fisheries
Archives of Urology
Archives of Zoological Studies
Atmospheric & Earth Sciences
Biotech Research & Biochemistry
Brain & Neuroscience Research
Cancer Biology and Treatment
Cardiology and Neurocardiovascular Diseases
Cell Biology & Cell Metabolism
Clinical Dermatology and Therapy
Clinical Immunology & Immunotherapy
Clinical Studies and Medical Case Reports
Community Medicine & Public Health Care
Current Trends: Medical & Biological Engineering
Cytology & Tissue Biology
Dentistry: Oral Health & Cosmesis
Diabetes & Metabolic Syndrome Disorders
Emergency Medicine, Trauma and Surgical Care
Environmental Science: Current Research
Food Science & Nutrition
Forensic, Legal & Investigative Sciences
Gastroenterology & Hepatology Research
Genetics & Genomic Sciences
Gerontology & Geriatric Medicine
Hematology, Blood Transfusion & Disorders
Hospice & Palliative Medical Care
Human Endocrinology
Infectious & Non Infectious Diseases
Internal Medicine and Primary HealthCare
Laser Research & Applications
Medicine: Study & Research
Modern Chemical Sciences
Nanotechnology: Nanomedicine & Nanobiotechnology
Neonatology and Clinical Pediatrics
Nephrology & Renal Therapy
Non-invasive Vascular Investigations
Nuclear Medicine, Radiology & Radiation Therapy
Obesity & Weight Loss
Ophthalmology & Clinical Research
Orthopedic Research & Physiotherapy
Otolaryngology, Head and Neck Surgery
Pathology: Clinical & Medical Research
Pharmacology, Pharmaceutics & Pharmacovigilance
Physical Medicine, Rehabilitation & Disabilities
Plant Science: Current Research
Practical and Professional Nursing
Protein Research & Bioinformatics
Psychiatry, Depression and Anxiety
Pulmonary Medicine & Respiratory Research
Reproductive Medicine, Gynaecology and Obstetrics
Stem Cells Research, Development & Therapy
Surgery: Current Trends & Innovations
Toxicology: Current Research
Translational Science and Research
Vaccines Research and Vaccination
Virology & Antivirals

Submit Your Manuscript: <http://www.heraldopenaccess.us/Online-Submission.php>