

Photo Essay

Axenfeld-Rieger Syndrome: Photo Essay

Mohamed Abdallahi Ould Hamed*, Abdoulsalam Youssoufou Soulay, Karim Reda and Abdelbarre Oubaaz

Department of Ophthalmology, Med V Military Hospital of Rabat, Morocco

Abstract

We report the case of a patient aged 47 who consult for a decrease in visual acuity. Examinations of the anterior segment spotting unilateral irrido-trabecular dysgenesis of the right eye with abnormal visibility of the Schwabe line corresponding to a posterior Embryotoxon and associated angular abnormalities. The eye tone measured with Goldman tonometer showed 14mmHg in the right eye and 15mmHg in the left eye. The examination of the fundus of the eye finds symmetrical morphology of the optic discs without pathological papillary excavation.

Keywords: Axenfeld-Rieger syndrome; Irrido-trabecular dysgenesis; Embryotoxon

Photo Essay

We report the case of a patient aged 47 who consult for a decrease in visual acuity. Examination of the anterior segment spotting unilateral irrido-trabecular dysgenesis of the right eye with abnormal visibility of the Schwabe line corresponding to a posterior embryotoxon and associated angular abnormalities (Figures 1,2&3). The eye tone measured with Goldman tonometer showed 14mmHg in the right eye

***Corresponding author:** Mohamed Abdallahi Ould Hamed, Department of Ophthalmology, Med V Military Hospital of Rabat, Morocco, Tel: +212 655835932; E-mail: badahick@gmail.com

Citation: Hamed MAO, Soulay AY, Reda K, Oubaaz A (2018) Axenfeld-Rieger Syndrome: Photo Essay. J Ophthalmic Clin Res 5: 42.

Received: May 03, 2017; **Accepted:** May 21, 2018; **Published:** June 04, 2018

Copyright: © 2018 Hamed MAO, et al. This is an open-access article distributed under the terms of the Creative Commons Attribution License, which permits unrestricted use, distribution, and reproduction in any medium, provided the original author and source are credited.

and 15mmHg in the left eye. The examination of the fundus of the eye finds symmetrical morphology of the optic discs without pathological papillary excavation.

The remainder of the somatic examination reveals no abnormality associated especially the absence of dental malformation. Chronic glaucoma is seen in 50% of patients [1].

The diagnosis of Axenfeld-Reiger syndrome uncomplicated of chronic glaucoma has been established, despite the absence of signs of Rieger [1].

No treatment has been established. Regular checks have been proposed to detect any complications including glaucoma.

This syndrome is inherited as an autosomal dominant manner. 2 genes are mainly involved in the transmission: the PITX2 gene in 4q25, present in 10-60% of patients, mainly associated with systemic alterations such as dental malformations [2,3]. The other gene responsible is FOXC1 located in 6q25, present in 50% of cases and manifested by ocular alterations, especially glaucoma [2-4].

The differential diagnosis arises with the Peters anomaly which consists of a defect of the posterior surface of the cornea associated with a stromal opacity. Currently, it is suggested that all these abnormalities are actually part of the same syndrome: Axenfeld-Rieger syndrome [5].

Conflict of interest

The authors declare no conflict of interest.

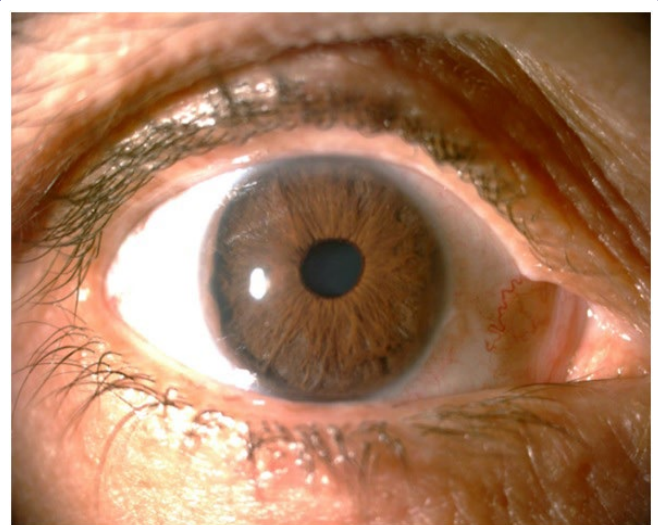


Figure 1: Embryotoxon on the temporal side of the right eye.

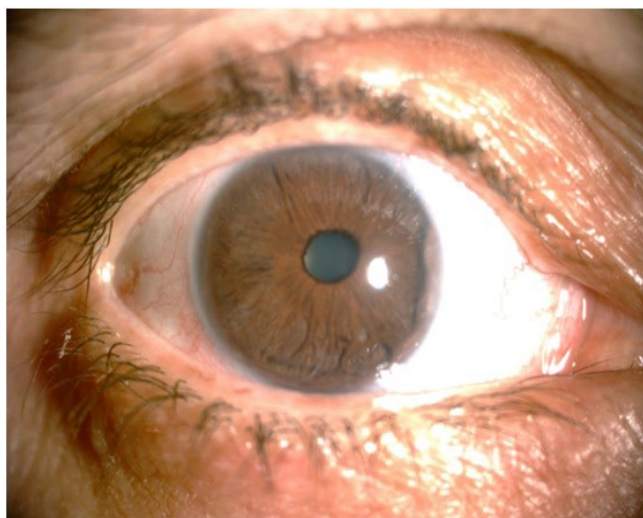


Figure 2: Embryotoxon on the nasal side of the right eye.

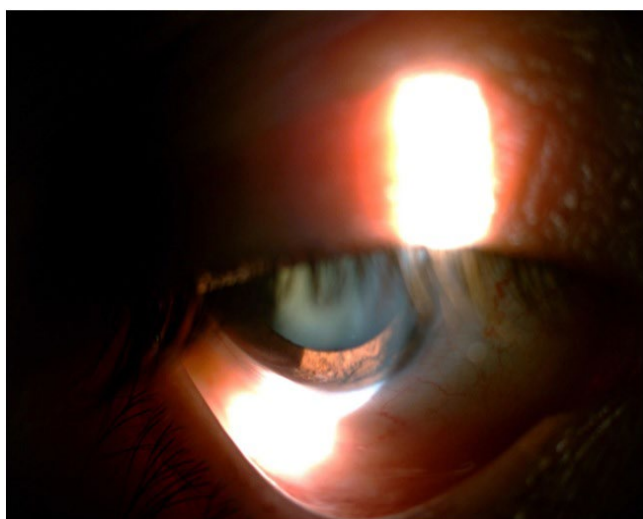


Figure 3: Angular abnormalities of the right eye.

References

1. Alward WL (2000) Axenfeld-Rieger syndrome in the age of molecular genetics. *Am J Ophthalmol* 130: 107-115.
2. Reis LM, Tyler RC, Volkmann Kloss BA, Schilter KF, Levin AV, et al. (2012) PITX2 and FOXC1 spectrum of mutations in ocular syndromes. *Eur J Hum Genet* 20: 1224-1233.
3. Strungaru MH, Dinu I, Walter MA (2007) Genotype-phenotype correlations in Axenfeld-Rieger malformation and glaucoma patients. *Invest Ophthalmol Vis Sci* 48: 228-237.
4. Honkanen RA, Nishimura DY, Swiderski RE, Bennett SR, Hong S, et al. (2003) A family with Axenfeld-Rieger syndrome and Peters anomaly caused by a point mutation (Phe112Ser) in the FOXC1 gene. *Am J Ophthalmol* 135: 368-375.
5. Chang TC, Summers CG, Schimmenti LA, Grajewski AL (2012) Axenfeld-Rieger syndrome: New perspectives. *Br J Ophthalmol* 96: 318-322.