

## Case Report

### Balloon Assisted Technique in Peripheral Interventions: A Useful Tool

Pozzi Mucelli Fabio, Pozzi Mucelli Roberta Antea<sup>\*ID</sup>, Sacconi Francesca, Braini Massimiliano, Belgrano Manuel Gianvalerio and Cova Maria Assunta

Department of Radiology, Azienda Sanitaria Universitaria Integrata di Trieste, Trieste, Italy

#### Abstract

Balloon Assisted Technique (BAT) consists in the use of a balloon catheter advanced in a parallel fashion to main catheter in the same artery to overcome problems during endovascular interventions. We describe three different cases of BAT. The first case is an example of pancreatic-duodenal artery aneurysm treated with a flow-diverter stent; in the second case BAT was used to help the advancement of a covered stent in the renal artery during a "Chimney" deployment in an advanced EVAR procedure. The third case BAT allowed improving visibility and catheterization of a diaphragmatic artery feeding a small HCC during TACE procedure.

These are some possible applications of BAT technique. More than a technique we believe that BAT is a "maneuver" to be tailored for every complex situation with specific materials.

**Keywords:** Aneurysm; Balloon assisted technique; Endovascular procedures

#### Introduction

Balloon Assisted Technique (BAT) consists in the use of a balloon catheter advanced in a parallel fashion to the main catheter in the same artery to overcome problems during endovascular interventions. This technique is already quite often applied in neuroradiologic endovascular interventions, mainly for endovascular coiling of intracranial aneurysms with a wide neck, as proposed by Moret and known as "remodeling technique" [1]. Also cardiologists use balloon assisted tracking during coronary interventions and they have introduced the same acronym BAT. In peripheral endovascular interventions BAT

**\*Corresponding author:** Pozzi Mucelli Roberta Antea, Department of Radiology, Azienda Sanitaria Universitaria Integrata di Trieste, Trieste, Italy, Tel: +39 0403994372; E-mail: roberta.pozzimucelli@gmail.com

**Citation:** Pozzi Mucelli F, Pozzi Mucelli RA, Sacconi F, Braini M, Belgrano MG, Cova MA (2019) Balloon Assisted Technique in Peripheral Interventions: A Useful Tool. J Angiol Vasc Surg 4: 022.

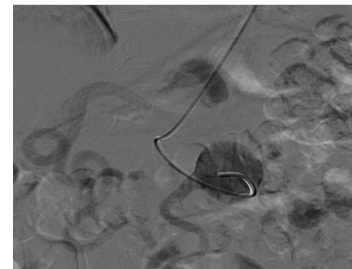
**Received:** March 28, 2019; **Accepted:** May 03, 2019; **Published:** May 10, 2019

**Copyright:** © 2019 Fabio PM, et al. This is an open-access article distributed under the terms of the Creative Commons Attribution License, which permits unrestricted use, distribution, and reproduction in any medium, provided the original author and source are credited.

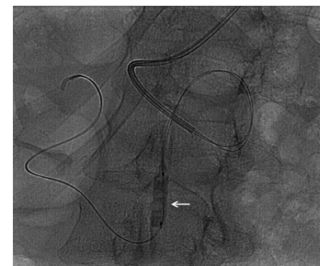
technique is rarely reported [2-5]. We describe some original applications of BAT of our experience.

#### Cases Description

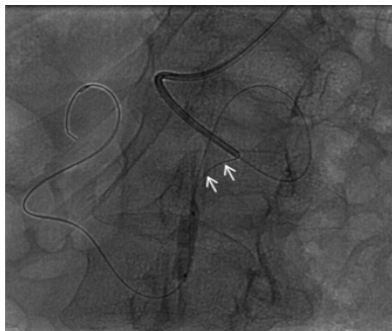
Giant aneurysm of pancreatic-duodenal artery. Female, 65 yrs Abdominal CT exam identified a 5 cm aneurysm of pancreatic-duodenal artery probably due to occlusion of the origin of the celiac trunk caused by Dunbar Syndrome. Follow-up CT demonstrated a mild enlargement of the aneurysm and for this reason an endovascular treatment was proposed. Coiling of the aneurysm was rejected due to the risk of occlusion of the parent artery feeding the gastroduodenal, hepatic and splenic artery and we considered to exclude the aneurysm with a flow-diverter stent. Procedure was done in local anesthesia using brachial approach. After Superior Mesenteric Artery (SMA) catheterization a 6F guiding catheter (Envoy Cardinal Health) was advanced at the origin of the pancreatic-duodenal artery, close to the aneurysm (Figure 1a). A .014 guidewire (V14 Boston) was advanced distally to the aneurysm, but with a large "loop" inside it (Figure 1b). For this reason, a second .014 wire was advanced parallel to the first one and a rapid exchange 7 mm balloon (Sterling Boston) was inflated close to the distal end of the first wire (Figure 1b). The first wire was gently retracted until the "loop" disappeared (Figure 1c). Also the second wire could be straightened and guiding catheter was advanced distal to the aneurysm. In this way the flow diverter stent easily advanced in the correct position and deployed (Figure 1d). CT follow-up after 20 days showed correct position of the flow diverter and exclusion of the aneurysmatic sac (Figure 1e).



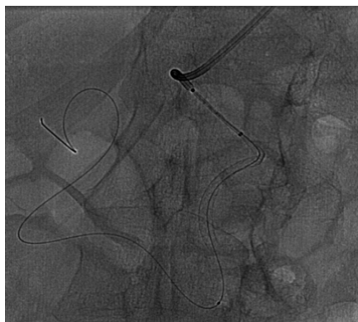**Figure 1a:** A 65 yrs woman with aneurysm of pancreatic-duodenal artery; guiding advanced at the origin of the pancreatic-duodenal artery, close to the aneurysm.



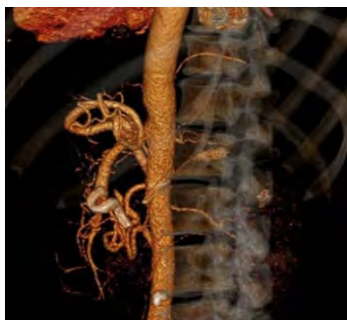**Figure 1b:** A 65 yrs woman with aneurysm of pancreatic-duodenal artery; guide wires advanced distally to the aneurysm, but with a large "loop" inside it. Second wire was advanced parallel to first and rapid exchange balloon (arrow) was inflated close to distal end of first wire.



**Figure 1c:** A 65 yrs woman with aneurysm of pancreatic-duodenal artery; in this way the first wire could be gently retracted until “loop” disappeared (small arrows).



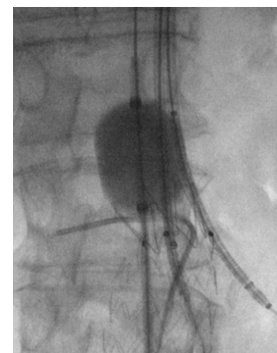
**Figure 1d:** A 65 yrs woman with aneurysm of pancreatic-duodenal artery; also second wire was straightened and guiding catheter was advanced distal to the aneurysm, allowing the flow diverter stent to be easily advanced in the correct position and deployed.



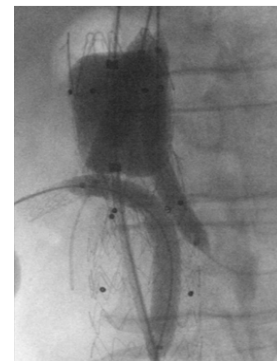**Figure 1e:** A 65 yrs woman with aneurysm of pancreatic-duodenal artery; CT follow-up after 3 months showed correct position of the flow diverter and exclusion of the aneurysmal sac.

Abdominal aortic aneurysm treated with parallel stent grafting technique. Male, 75 yrs an asymptomatic juxtarenal abdominal aortic aneurysm of 5 cm of maximum diameter, was detected during abdominal US performed for unrelated pathology. CT-angiography confirmed the lesion starting just below the origin of SMA and involving both renal arteries. Patient preferred to be treated immediately instead of undergoing an imaging surveillance. An advanced EVAR treatment was planned with “parallel” stenting of both renal arteries and SMA because at that time this was our first choice of treatment for these

type aneurysms. After surgical cut-down of the axillary artery two long introducer-sheaths were advanced, one in SMA and one in left renal artery. Right renal artery was approached from one of two femoral accesses; however advancement of stiff guidewire (Amplatz Super stiff-Boston) was problematic due to unfavorable angle. For this reason we decided to inflate an occlusion balloon (Reliant Medtronic) just over the origin of renal arteries while advancing the stiff wire in the right renal artery (Figure 2a) and after this, with the same modality, a 7F long introducer sheath (Destination Terumo) was introduced inside the artery (Figure 2b). After correct positioning of all sheaths the balloon covered stents were advanced and deployed at the origin of target vessels and EVAR treatment was completed as usual (Figure 2b).



**Figure 2a:** A 75 yrs man with asymptomatic iuxtarenal abdominal aortic. An advanced EVAR treatment was planned with “parallel” stenting of both renal arteries and SMA; an occlusion aortic balloon was inflated just over the origin of renal arteries giving support to a stiff wire that could be advanced in the right renal artery.



**Figure 2b:** A 75 yrs man with asymptomatic iuxtarenal abdominal aortic. An advanced EVAR treatment was planned with “parallel” stenting of both renal arteries and SMA; after a 7F long introducer sheath was introduced inside the artery and all balloon covered stents were advanced and deployed at the origin of target vessels.

Transarterial Chemoembolization (TACE) for Hepatocellular Carcinoma (HCC) with atypical feeding artery. Male, 68 yrs History of HCC treated with multiple chemoembolization procedures. At CT follow-up an incomplete response was detected in a nodule of the 7<sup>th</sup> segment and a feeding artery supplied by right diaphragmatic artery was suspected. Selective angiography of celiac trunk was done but visualization of right diaphragmatic artery was faint. To increase visibility of this artery a second femoral access was done and a balloon catheter inflated in the proximal celiac trunk improving detection of

right diaphragmatic artery which was then easily catheterized. Selective injection confirmed feeding artery to the 7<sup>th</sup> segment HCC nodule and TACE procedure could be done.

## Discussion

The use of BAT in peripheral interventional radiology is rarely reported and just some case reports can be found in literature: in performing carotid stenting [2], to advance long sheaths through freshly placed stents or anatomical difficult vessels [3], to enable superselective catheterization of inaccessible small arteries [4], to remove inferior vena cava tilted filter with apex in contact with caval wall and covered by an endothelial cap [5]. Our 3 cases show further applications of BAT. In the first case BAT is used to straighten a guidewire in order to favor the advancement of a stent, while in the second case it was used to push a stiff guidewire in a renal artery with an unfavorable angle. In the last case BAT improved visualization of a small artery, such as the diaphragmatic artery. More than a technique we believe that BAT is a “maneuver” to be tailored for every complex situation with specific materials to resolve complex situations. In our center only more expert interventionalists have used this “maneuver” and usually as last option, in complex cases, as the ones here described. It must be emphasized that possible complications, as dissections, due to balloon inflation, may occur, also if in our limited experience this was not observed.

## Conclusion

These are some possible applications of BAT. Based on our experience we believe that in every difficult interventional radiologic procedure, BAT should be considered as a helpful way to solve complicated maneuvers. More than a technique we feel that BAT is a “maneuver” to be tailored for every complex situation with specific materials.

## Conflict of Interest

This research did not receive any specific grant from funding agencies in the public, commercial, or not-for-profit sectors.

## References

1. Moret J, Cognard C, Weill A, Castaings L, Rey A (1997) [Reconstruction technic in the treatment of wide-neck intracranial aneurysms. Long-term angiographic and clinical results. Apropos of 56 cases]. *J Neuroradiol* 24: 30-44.
2. Cohen JE, Gomori JM, Itshayek E (2011) Balloon-assisted looping technique to perform carotid artery stenting. *J Clin Neurosci* 18: 1538-1540.
3. Prieto LR, Bellotti CA (2013) Balloon-assisted techniques for advancing long sheaths through difficult anatomy. *Pediatr Cardiol* 34: 1125-1129.
4. Chen MC, Chang SC, Weng MJ, Tzeng WS, Wu RH, et al. (2006) Use of angioplasty balloon-assisted Seldinger technique for complicated small vessel catheterization. *J Vasc Interv Radiol* 17: 2011-2013.
5. Lynch FC (2009) Balloon-assisted removal of tilted inferior vena cava filters with embedded tips. *J Vasc Interv Radiol* 20: 1210-1214.



Journal of Anesthesia & Clinical Care  
Journal of Addiction & Addictive Disorders  
Advances in Microbiology Research  
Advances in Industrial Biotechnology  
Journal of Agronomy & Agricultural Science  
Journal of AIDS Clinical Research & STDs  
Journal of Alcoholism, Drug Abuse & Substance Dependence  
Journal of Allergy Disorders & Therapy  
Journal of Alternative, Complementary & Integrative Medicine  
Journal of Alzheimer's & Neurodegenerative Diseases  
Journal of Angiology & Vascular Surgery  
Journal of Animal Research & Veterinary Science  
Archives of Zoological Studies  
Archives of Urology  
Journal of Atmospheric & Earth-Sciences  
Journal of Aquaculture & Fisheries  
Journal of Biotech Research & Biochemistry  
Journal of Brain & Neuroscience Research  
Journal of Cancer Biology & Treatment  
Journal of Cardiology: Study & Research  
Journal of Cell Biology & Cell Metabolism  
Journal of Clinical Dermatology & Therapy  
Journal of Clinical Immunology & Immunotherapy  
Journal of Clinical Studies & Medical Case Reports  
Journal of Community Medicine & Public Health Care  
Current Trends: Medical & Biological Engineering  
Journal of Cytology & Tissue Biology  
Journal of Dentistry: Oral Health & Cosmesis  
Journal of Diabetes & Metabolic Disorders  
Journal of Dairy Research & Technology  
Journal of Emergency Medicine Trauma & Surgical Care  
Journal of Environmental Science: Current Research  
Journal of Food Science & Nutrition  
Journal of Forensic, Legal & Investigative Sciences  
Journal of Gastroenterology & Hepatology Research  
Journal of Gerontology & Geriatric Medicine  
Journal of Genetics & Genomic Sciences  
Journal of Hematology, Blood Transfusion & Disorders  
Journal of Human Endocrinology  
Journal of Hospice & Palliative Medical Care  
Journal of Internal Medicine & Primary Healthcare  
Journal of Infectious & Non Infectious Diseases  
Journal of Light & Laser: Current Trends  
Journal of Modern Chemical Sciences  
Journal of Medicine: Study & Research  
Journal of Nanotechnology: Nanomedicine & Nanobiotechnology  
Journal of Neonatology & Clinical Pediatrics  
Journal of Nephrology & Renal Therapy  
Journal of Non Invasive Vascular Investigation  
Journal of Nuclear Medicine, Radiology & Radiation Therapy  
Journal of Obesity & Weight Loss  
Journal of Orthopedic Research & Physiotherapy  
Journal of Otolaryngology, Head & Neck Surgery  
Journal of Protein Research & Bioinformatics  
Journal of Pathology Clinical & Medical Research  
Journal of Pharmacology, Pharmaceutics & Pharmacovigilance  
Journal of Physical Medicine, Rehabilitation & Disabilities  
Journal of Plant Science: Current Research  
Journal of Psychiatry, Depression & Anxiety  
Journal of Pulmonary Medicine & Respiratory Research  
Journal of Practical & Professional Nursing  
Journal of Reproductive Medicine, Gynaecology & Obstetrics  
Journal of Stem Cells Research, Development & Therapy  
Journal of Surgery: Current Trends & Innovations  
Journal of Toxicology: Current Research  
Journal of Translational Science and Research  
Trends in Anatomy & Physiology  
Journal of Vaccines Research & Vaccination  
Journal of Virology & Antivirals  
Archives of Surgery and Surgical Education  
Sports Medicine and Injury Care Journal  
International Journal of Case Reports and Therapeutic Studies

Submit Your Manuscript: <http://www.heraldopenaccess.us/Online-Submission.php>