

## Review Article

### Truncular Venous Malformations: Venous Aneurysm Case Series in a General Hospital

Felipe Gerardo Rendón Elías<sup>1\*</sup>, Fernando Vega Rasgado<sup>2</sup>,  
Marely Hernández Sánchez<sup>1</sup> and Luis Gómez Danés<sup>1</sup>

<sup>1</sup>Centro Universitario de Flebología y Malformaciones Vasculares, Servicio de Cirugía Torácica y Cardiovascular, Hospital Universitario "Dr. José Eleuterio González", Nuevo León, México

<sup>2</sup>Department of General Surgery, Instituto Mexicano de Flebología, Ciudad de México, México

#### Abstract

**Background:** Primary venous aneurysm corresponding to the truncular venous malformations or to the malformations of major named vessels according to the Hamburg classification and the updated classification from International Society for the Study of Vascular Anomalies respectively. Venous aneurysms are considered an infrequent clinical entity and their natural history and treatment depends of their size and location.

**Method:** A systematic retrospective analysis of clinical records from patients with the diagnosis of truncular venous malformations type superficial venous aneurysms in the period from September 2014 to December 2017 was reviewed.

**Result:** A total of 25 patients were identified. The anatomic location of the truncular venous a malformation was neck (7 patients), in the upper extremities (6 patients) and in the lower extremities (12 patients). The patient's presentation comprised: pain, swelling, thrombosis, aesthetic discomfort and asymptomatic mass. Treatment was surgical in the most of the cases.

**Conclusion:** Primary venous aneurysms are not rare and they must not be considered just as a varicose vein. The diagnosis is made by a clinical history and physical examination and corroborated with vascular ultrasound and in selected cases other imaging studies are indicated. Surgery is the best therapeutic strategy considering their potential morbidity and mortality.

**Keywords:** Primary venous aneurysm; Vascular anomalies; Venous malformations

\*Corresponding author: Felipe Gerardo Rendón Elías, Centro Universitario de Flebología y Malformaciones Vasculares, Servicio de Cirugía Torácica y Cardiovascular, Hospital Universitario "Dr. José Eleuterio González", Nuevo León, México, Tel: + 81 83467800; + 81 834 88305; E-mail: drfrendon@gmail.com

**Citation:** Elías FGR, Rasgado FV, Sánchez MH, Danés LG (2019) Truncular Venous Malformations: Venous Aneurysm Case Series in a General Hospital. J Angiol Vasc Surg 4: 023.

**Received:** June 11, 2019; **Accepted:** July 17, 2019; **Published:** July 24, 2019

**Copyright:** © 2019 Elías FGR, et al. This is an open-access article distributed under the terms of the Creative Commons Attribution License, which permits unrestricted use, distribution, and reproduction in any medium, provided the original author and source are credited.

#### Introduction

According to the updated ISSVA (International Society for the Study of Vascular Anomalies) new classification of Vascular Anomalies, Classification of Vascular Anomalies adopted the 'extratruncular versus truncular' concept of Hamburg Classification as a part of the efforts to improve/update their original Classification, through the workshop in Melbourne, Australia (April 2014) [1-4]; the venous malformations are divided in simple, combined, venous malformations of major named vessel (channel type or truncal) and associated with other anomalies.

Truncular venous malformations affecting the major named vessel regarding abnormal caliber of the vein can be presented either as stenosis/obstruction or dilatation known as venomegalia (phlebectasia) or aneurysm [5,6], as the outcome of aplasia, hypoplasia, or hyperplasia following defective development during the latter stage of embryogenesis [6,7].

The purpose of this article is to present our experience of patients with superficial truncal venous malformations type aneurysm affecting neck, upper extremities, lower extremities and additionally, the literature is reviewed with a discussion on clinical implications and the diagnostic and therapeutic approach of this lesser known vascular pathology.

#### Patients and Methods

In a systematic retrospective review of clinical records, we analyzed data from patients with the diagnosis of truncular venous malformations from September 2014 to December 2017. From the patients with truncular venous malformations we just selected the patients from any age with diagnosis of primary superficial venous aneurysm (see the definition below) in the venous system of the lower extremities, the upper extremities, and in the neck. The diagnosis was made by a clinical history and physical examination and corroborated with imaging diagnoses using Doppler Ultrasonography (DUS) in all patients and MRI or TAC just in selected patients.

In this article the terminology used to describe venous dilatations were: 1) phlebectasia or venomegalia defined as a diffuse dilatation of one or more veins with a caliber increase  $\geq 50\%$  compared with normal [8,9] 2) primary venous aneurysm is defined as a solitary area of venous dilatation that is  $\geq 1.5$  times the diameter of the normal proximal and distal vein size [10,11], that containing all 3 layers of the vein wall that communicates with a main venous structure by a single channel and must have no association with an arteriovenous communication or pseudoaneurysm, nor be related to a varicose vein (chronic venous insufficiency) [12]. We just included patients that met the required criteria to classify her venous pathology as a primary venous aneurysm and we reviewed hospital records for patient's demographic characteristics, clinical presentation, diagnosis approach, treatment and evolution.

## Results

A total of 25 patients were identified. The diagnosis was based on clinical history and corroborated with radiologic investigations. Fourteen patients (56%) were male and eleven (44%) female. The age of presentation was a range of 2-62 years of age. The anatomic location of the truncular venous a malformation was neck (7 patients), in the upper extremities (6 patients) and in the lower extremities (12 patients). The patient's presentation comprised: pain (12 patients), swelling (1 patients), Thrombosis (6 patients), aesthetic discomfort (4 patients) and asymptomatic mass (7 patients).

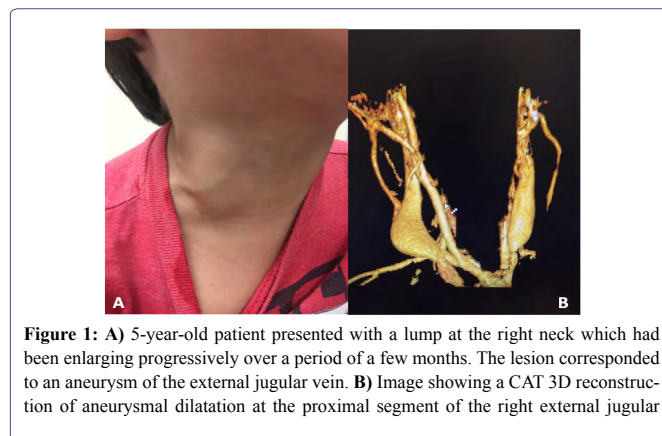
### Truncular venous malformations in the neck (Table 1)

There were 7 patients, 5 males and 2 females, the age range were 2-24 years of age, none patient has an important medical history, the clinical presentation were an asymptomatic non pulsating mass in all patients, and five cases localized in the right side. The diagnosis was made by clinical history and corroborated with DUS in all patients and just two of them MRI and CAT were needed (Figure 1). Three patients received surgical treatment that consisted in resection of the affected vein and the indication in two of them was for aesthetic reason and the other one for parent's preferences. There were not complications and the evolution has been good.

### Truncular venous malformations in the upper extremities (Table 2)

In this group there was six patients, four women and two men, the age range was 3-53 years of age, none patient has an important medical history, the presentation was pain and thrombosed in five patients and in one was a nonpulsating mass which occasioned aesthetic discomfort (Figure 2). In all these patients just required Doppler ultrasound and none has a clinical dates of thromboembolism complications to require more imagines studies. Average aneurysm size was

2.9 cm ranging from 2.2 to 5.3 cm. All patients received surgical treatment consisted in resection of the venous aneurysm. The patients with thrombosis received a short course of oral anticoagulants. There were no complications and the evolution was good.



**Figure 1:** A) 5-year-old patient presented with a lump at the right neck which had been enlarging progressively over a period of a few months. The lesion corresponded to an aneurysm of the external jugular vein. B) Image showing a CAT 3D reconstruction of aneurysmal dilatation at the proximal segment of the right external jugular

### Truncular venous malformations in the upper extremities (Table 2)

In this group there was six patients, four women and two men, the age range was 3-53 years of age, none patient has an important medical history, the presentation was pain and thrombosed in five patients and in one was a nonpulsating mass which occasioned aesthetic discomfort (Figure 2). In all these patients just required Doppler ultrasound and none has a clinical dates of thromboembolism complications to require more imagines studies. Average aneurysm size was 2.9 cm ranging from 2.2 to 5.3 cm. All patients received surgical treatment consisted in resection of the venous aneurysm. The patients with thrombosis received a short course of oral anticoagulants. There were no complications and the evolution was good.

**Truncular Venous Malformations in the Neck**

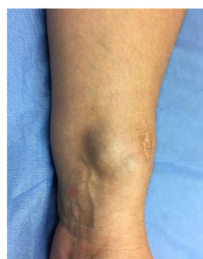	Sex	Age	Site	Medical history	Presentation	Treatment
Case 1	M	3	Right External jugular vein	None	Asymptomatic nonpulsating mass	Conservative
Case 2	M	2	Right External Jugular Vein	None	Asymptomatic nonpulsating mass	Conservative
Case 3	F	24	Left Internal Jugular Vein	None	Aesthetic Discomfort	Surgery
Case 4	F	13	Right External Jugular Vein	None	Aesthetic Discomfort	Surgery
Case 5	M	5	Right Internal Jugular Vein	None	Asymptomatic nonpulsating mass	Conservative
Case 6	M	3	Left External Jugular Vein	None	Asymptomatic nonpulsating mass	Conservative
Case 7	M	5	Right External Jugular Vein	None	Asymptomatic nonpulsating mass, fear of his parents	Surgery

**Table 1:** Truncular venous malformations in the neck.

**Truncular Venous Malformations in the Neck**

	Sex	Age	Site	Medical history	Presentation	Treatment
Case 8	M	47	Left Cephalic Vein	None	Pain, Thrombosis	Surgery
Case 9	F	38	Right Radial Vein	None	Pain, Thrombosis	Surgery
Case 10	F	53	Right Basilic Vein	None	Pain, Thrombosis	Surgery
Case 11	F	28	Right Medial Cubital Vein	None	Pain, Thrombosis	Surgery
Case 12	F	23	Right Dorsal Venous Arch	None	Non Pulsating Mass, Aesthetic Discomfort	Surgery
Case 13	M	3	Left Basilic Vein	None	Pain, Thrombosis	Surgery

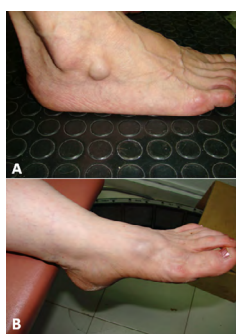**Table 2:** Truncular venous malformations in the upper extremities.



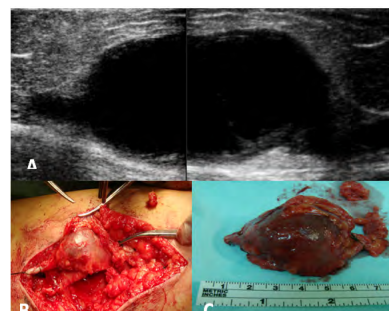
**Figure 2:** 38-year-old patient presented with painful mass at the right forearm. The lesion corresponded to an aneurysm of the right radial vein external.

### Truncular venous malformations in the lower extremities (Table 3)

In the lower extremities there was 12 patients, seven men and five women, the age range was 18-62 years of age, the presentation was a painful nonpulsating mass in 5 patients, thrombosis in 1 patient, acute edema in 1 patient, aesthetic discomfort in 1 patient and in 5 patients with an asymptomatic nonpulsating mass. The most common location was the great saphenous vein (right: 7 patients) (Figures 3 and 4) Just the patient with acute edema required an angio-TAC beside the vascular ultrasound. Average aneurysm size was 4cm ranging from 3.8 to 12.4 cm. All the patients received a surgical treatment consisted in resection of the venous aneurysm. There were no complications and the evolution was good.



**Figure 3:** A) 52-year-old patient presented with a compressible mass in the lateral portion of the right venous dorsal foot arch B) 56-year-old patient presented with asymptomatic mass at the left venous dorsal foot arch that cause esthetic discomfort.



**Figure 4:** A) Reconstructed ultrasound image which shows an internal saphenous vein venous aneurysm of 9 × 5 cm B) Surgical excision of the internal saphenous vein venous aneurysms. C) Thrombosed internal saphenous vein venous aneurysm.

### Discussion

This article is just a descriptive article with additional medical review, the number of cases is low to compare with other studies or make conclusions, indeed other articles just talking about personal experience and the treatment choice is personal decision. The purpose of this article is just for create consciousness and realize that venous aneurysm exists and they are not just varicose veins.

Vascular anomalies in the past were confused by ambiguous and inconsistent nomenclature, leading to inappropriate treatment and misdirect research efforts. To avoid these problems, two classification systems have been established based on the workshop held in Hamburg, Germany in 1988 [2,13-15] and the other proposed by Mulliken and Glowacki, now adopted by the ISSVA in 1996 (last update in 2018) [1,15-18]. In the Hamburg Classification (HC), accounts for the underlying anatomical, histological, and pathophysiological features of congenital vascular malformations. It also introduces embryological aspects, further subdividing them into either an extratruncular or truncular form, based on the time of developmental arrest during embryonic life. In the ISSVA classification the vascular anomalies are divided in vascular tumors and vascular malformations. Vascular malformations are divided into four groups: simple malformations, combined malformations, malformations of major named vessels which are equivalent to “truncular” type malformation by Hamburg Classification and the malformations associated with other anomalies. Simple malformations are categorized by the type of vessel involved: capillaries, lymphatics, veins or arteries.

**Truncular Venous Malformations in Lower Extremities**

	Sex	Age	Site	Medical history	Presentation	Treatment
Case 14	F	62	Right GSV*	None	Pain, Non Pulsating Mass	Surgery
Case 15	F	48	Right GSV*	None	Pain, NonPulsating Mass	Surgery
Case 16	F	37	Right GSV*	None	Pain, NonPulsating Mass	Surgery
Case 17	M	56	Right GSV*	None	Pain	Surgery
Case 18	M	61	Left GSV*	None	Asymptomatic, Non Pulsating Mass	Surgery
Case 19	M	28	Right GSV*	None	Asymptomatic non pulsating mass	Surgery
Case 20	F	53	Right GSV**	None	Pain, Thrombosis	Surgery
Case 21	M	48	Posterior Arch of GSV	None	Asymptomatic	Surgery
Case 22	M	18	Right small saphenous vein	None	Acute swelling of the leg	Surgery
Case 23	F	56	Left venous dorsal foot arch	None	Asymptomatic, non pulsating mass, aesthetic discomfort	Surgery
Case 24	F	52	Right venous dorsal foot arch	None	Pain	Surgery
Case 25	M	41	Right GSV**	None	Pain, Non pulsating mass	Surgery

**Table 3:** Truncular Venous Malformations in the Lower Extremities.

They affect only one type of vessel, with the exception of arteriovenous malformation that affects arteries, veins and capillaries.

In ISSVA classification the AV belong to the group of the malformations of major named vessels that include malformations that affect veins, and consist of anomalies in the origin, course, number, length, diameter (aplasia, hypoplasia and ectasia/aneurysm) or valves. And in the HC the AV correspond to a venous malformation of the truncular type which can be presented as aplasia, hyperplasia, stenosis (i.e., the left iliac vein in May-Turner syndrome), dilations or aneurysms (the most common being the popliteal vein). For the knowledge of these classifications we decided to name our article like Truncular Venous Malformations: Superficial Venous Aneurysm.

The VA were first mentioned in the medical literature by Harris [19], he described an infant with congenital venous aneurysm of the mediastinum in 1928, and Hilscher [11] suggested the term of venous aneurysm, similar to arterial aneurysms.

More than one in the medical community think that VA are a very rare disorder even some believe that they do not exist and that every dilated veins are varicose vein for this reasons and the lacking of the epidemiologic data make to them a very rare pathology.

Venous aneurysms according to the etiopathogeny can be divided into primary (congenital) and secondary (acquired). The latter type is caused by trauma, by infection or venous valve insufficiency, or by an arteriovenous fistula, which is due to an increase in the venous blood flow [20]. Primary Venous Aneurysms (PVA) are less common but have been reported to occur in most major veins. PVA in the lower extremities (the most common location for VA) also can be classified into superficial AV or deep AV. The incidence of superficial venous aneurysms is approximately 0.1%, with a prevalence of 1.5%, equally in both sexes and it may occur at any age. In a study by Gillespie et al., [21], 77% of the venous aneurysms were located in the lower extremities (57% of which were in the deep venous system); 10% were located in the upper extremities; and 13% involved the internal jugular vein.

The terminology used to describe venous dilatations can cause confusion. The terms phlebectasia, varicose vein and/or venous aneurysm are considered synonyms in the medical vocabulary; however, they mean different things. Phlebectasia is defined as a fusiform and diffusely dilated vein. The association of dilated and tortuous veins is known as varicose veins [22]. There are no precise criteria regarding size to consider a venous dilation like an aneurysm; however, Mateo [12] and McDevitt [23] established that whenever the vein's diameter is twice as large as the normal diameter, then it is considered to be an aneurysm [24]. Nevertheless, in order to consider it a primary venous aneurysm size is not the only factor considered. It must also be a localized dilation, conformed by three histological layers which constitute the normal venous wall. This could be saccular or fusiform (an important distinction because of its hemodynamic implications that influence the course of treatment) and should only communicate to the corresponding vein in a proximal and distal manner and neither be secondary to an arteriovenous fistula, nor be related to a varicose vein [25]. Abbott was the one who integrated the criteria to define VA [11]. All our patients met the required criteria to classify her venous pathology as a primary venous aneurysm.

The etiology of a PVA is difficult to understand. The much localized nature of these lesions suggests a specific abnormality in the vein wall. The histologic findings in some cases of VA vary from a normal

vein wall to marked medial disruption and inflammation. In all these changes of the vein wall the tyrosine kinase receptor TIE2, located on Endothelial Cells (ECs), and its ligand Angiopoietin-1 (ANG-1), secreted by vascular smooth muscle cells (that play a major role in the maturation and stability of veins) may be involved in the origin of the VA [26-30]. The malfunction of the TIE2 could be the guilty factor that provoke the venous remodeling termed endophlebohypertrophy and endo phleboscclerosis that different researches think that they may be important factors in the development of VA. Also in a recent study, tissue from the wall of venous aneurysms was examined and it was reported that structural changes of the aneurysmatic wall can be related to the increased expression of metalloproteinase, which can be translated to a reduction of the muscle layer, fragmented elastic tissue, an increase in the fibrous tissue and infiltration of inflammatory cells [31]. Schatz and Fine [32] believed that endophlebohypertrophy was a major factor in the formation of VA, which begins with an increase in venous flow leading to a hypertrophy of the venous wall, then dilation and sclerosis. Lev and Saphir [33,34] found that endophlebohypertrophy begins at birth and is associated with areas of stress and endo phleboscclerosis (thinning of the vein wall) increase with age and occurs immediately adjacent to the artery.

### **Venous aneurysms in the neck**

Venous aneurysms are uncommon causes of the cervical masses [1]. It was recognized by Gruber [35] in 1875 and by Harris in 1928 [19]. The VA in the neck has also been described as venoma, venous cyst, congenital venous cyst or jugular phlebectasia. The JA occur equally between genders and are seen at any age, about the 75% of the cases are diagnosed in children [36].

Perhaps the reason why venous aneurysms are rare is due to the low intravascular pressure in the superior vena cava system [37,38]. Jugular Aneurysm (JA) can be saccular or fusiform, the latter is the most common presentation.

Typically, the clinical presentation of the JA is like a unilateral soft mass in the neck, it enlarges on straining, crying, coughing, and Valsalva maneuver. The mass is almost always asymptomatic, although some patients refer the feeling of constriction, sensation of choking and giddiness, bluish discoloration, discomfort during physical activity, swallowing, and cessation of voice during reading or speaking out load [39]. Several characteristics in the clinical examination of a neck mass are suggestive of venous aneurysm. These include easy compressibility, increase in size with Valsalva's maneuvers and absence of pain. The JA is more commonly on the right internal jugular vein and bilaterality is uncommon.

In the differential diagnosis of a cervical mass, lymphatic malformation, hemangioma, a laryngocele, an enterogenous cyst, thyroid swelling, lymphadenopathy, a thyroglossal cyst, a dermoid cyst and a branchial cleft cyst should be considered. Engorgement of the neck swelling during strain eliminates others than a laryngocele and jugular vein aneurysm [40,41]. The absence of air inside the lesion on plain roentgenography further eliminates the laryngocele [37].

Diagnosis of jugular vein aneurysms can be achieved by color Doppler US imaging (with and without Valsalva), computed tomographic angiography, magnetic resonance angiography imaging, and venography. The Doppler US is the diagnostic method of choice [42].

Because the JA is uncommon treatment guidelines are not established so the management of JA is controversial, especially in asymptomatic cases. Spontaneous rupture has never been described although massive bleeding during tonsillectomy has been reported [43]. The risk for thrombotic complications is very low, there is no report about pulmonary embolism and just very few cases of spontaneous thrombosis has been reported [44-47]. For this reasons, most doctors strongly recommended conservative treatment [41,42,48].

Other prefers to follow an aggressive approach with liberal surgical repair [49].

The arguments to choice a surgical treatment are fear of enlargement, fear of rupture, thromboembolic complications and cosmetic and psychologic consideration [50]. It also allows surgeons to get the exact histopathological diagnosis.

The surgical treatment in JA can be safely treated by excision and ligation. Whereas, an exclusion and bypass may be needed in some cases of a fusiform aneurysm to avoid complications (cerebral edema) [49,50].

In our series of Neck vein aneurysm, were most common localized in the right side, all unilateral, and presenting likes an asymptomatic soft mass compressible, changing its size with Valsalva's maneuvers. We just need a DUS to corroborate the diagnosis; just one patient came with us already with MRI. Before to decide a treatment the patients and the parents were informed about the benign evolutions of these anomalies, but one parents were afraid of the future evolution and the other women because aesthetic discomfort preferred the surgical treatment but careful follow up is an appropriate treatment for primary venous aneurysm in the neck.

### **Venous aneurysm in the upper extremities**

The upper extremities are the least common location for a VA (only 4.2% to 10% occur in the upper extremities) [21]. They can involve both superficial and deep venous system, can be fusiform or saccular and are typically described in middle-aged adults. However, they can also occur in childhood or the elderly. They are equally common in men and women. However, they have been observed more frequently in individuals with higher body mass indices [51]. Although generally the VA is a single lesion there are reports about multiple venous aneurysms in the upper extremity [52].

Patients with this condition usually have an asymptomatic subcutaneous mass that sometimes increases gradually in size and may be accompanied by the appearance of new symptoms [53]. The majority of upper extremity VA is initially noted due to aesthetic concerns regarding a soft mass that often enlarges with a Valsalva maneuver [54]. Complications in the upper extremities VA have been recognized, including rupture, venous obstruction and compression of adjacent structures [55,56].

With regard to diagnosis, history and directed physical examination will provide a great deal of information, particularly if attention is paid to positional changes in the morphology of the aneurysm. These maneuvers will help to differentiate venous aneurysms from soft tissue tumors, which have often been reported as the initial diagnosis. Duplex ultrasonography and venography provide significant information regarding the anatomy and physiologic impact of these venous aneurysms. Axial imaging, including both CT and Magnetic

Resonance Imaging (MRI), provide additional information regarding the size of the aneurysm along with their relation to surrounding structures [56-58].

The treatment of VA of the upper extremities is less well-defined; based on the limited experience with upper extremity venous aneurysms; it remains unclear whether aggressive surgical management is warranted, particularly for asymptomatic patients, as resection is not without associated morbidity [59]. Since primary superficial VA has no life-threatening complication without thrombus, if the patient has no symptoms or cosmetic demands, regular follow-up may be advised and occurred in the current case. Otherwise, surgical excision can be considered [60].

All our cases in the upper extremities had the characteristics of primary VA, DUS played an important role in the diagnosis, because the most common presentation in our series was thrombosis there was no problem to chosen the surgical treatment to avoid complications, such as pulmonary embolism and one was for cosmetic demand. If the patient is asymptomatic conservative treatment is a good election and regular follow-up may be advised.

### **Venous aneurysm in the lower extremities**

Venous aneurysms in the lower extremities also can be divided into aneurysms of the deep and superficial venous systems. This distinction is important, because aneurysms of the deep system appear to have a greater association with thromboembolism and more severe venous morbidity than those of the superficial system. Aneurysms of the superficial venous system of the lower extremities were once thought to be exceedingly rare, but Pascarella et al., [61] showed they are more common than previously thought. In their report, 366 patients were screened with duplex ultrasound imaging, which identified 65 superficial venous aneurysms in 43 patients, of which 61 were in the GSV, and only 4 were found, as in our experience, to be in the SSV. The finding that only 6% of superficial venous aneurysms were in the SSV confirms an earlier report by Gillespie et al., [21] and underscores the unique nature of the two patients presented in this experience.

The clinical presentation of superficial VAs in lower extremities is that of a palpable soft lump. It can change its size and location with the body's position or the Valsalva maneuver; they can be completely asymptomatic or painful with edema.

The diagnosis can be made by the clinical history and physical examination in most cases, but it is usually confirmed by image studies. Within image studies, vascular ultrasound is the method of choice for the study of Vas [62]. In the ultrasound, VAs are presented as an anechoic cystic structure, with well-defined walls, which can be saccular or fusiform and with a low flow volume; also, they provide us with information on vascular connections, the existence of thrombosis, or if there is an associated arteriovenous fistula or any other pathologies [63], in addition to guiding the therapeutic approach. The CAT scan, the MRI and the phlebography are studies which can be performed in case of diagnostic doubt or when more exact information is required (size, extension, associated lesions and vascular origin) [64]. Clinical history and examination are the basis for reaching any diagnosis, but in the case of venous problems, vascular ultrasound evaluation is fundamental to reaching a correct diagnosis, and thus choosing the proper treatment. It is only in case of doubt, where further imaging studies

are required. In the differential diagnosis, we must consider varicose veins, soft tissue tumors, lymphatic malformations, hemangiomas and, depending on location, inguinal hernias. VA complications are: thrombophlebitis, deep venous thrombosis, pulmonary embolism and bleeding caused by rupture.

Coagulation disorders associated with VAs are characterized by blood stasis in the dilated vessels and with a low blood flow, which activates the coagulation cascade with the subsequent production of thrombin and the conversion of fibrinogen into fibrin [65,66]. Then the fibrinolysis process begins which is reflected in the rise in fibrinogen derived products, including D-dimer. This is the simplified description of located intravascular coagulopathy which characterizes coagulopathy associated with venous malformations [67,68]. Newly formed microthrombus attach to calcium and phleboliths are formed [69,70]. These can be detected during physical examination and verified by imaging studies. The presence of phleboliths in VAs can indicate treatment with anticoagulants, especially in large and extensive VAs [71]. Localized intravascular coagulopathy is of utmost importance because it is linked to the presence of local pain, thrombophlebitis, deep venous thrombosis and pulmonary embolism.

Even though deep venous aneurysms are more susceptible to presenting pulmonary embolism and their frequency is more common in this type of VA, superficial VAs are not free from presenting this complication. Due to this, they must be treated with anticoagulant therapy, just as the deep ones. Regarding the risk of VA rupture, it represents something theoretical since there are no reported cases of this complication.

Superficial VA treatment can be conservative, endovascular or surgical. If the VA is not too large and does not cause symptoms it may be treated conservatively through compressive therapy and prophylaxis in order to avoid thrombophlebitis or deep venous thrombosis. The indications for surgical treatment in superficial VAs are: the presence of symptoms, the risk of thrombosis, compression of nearby structures and, more commonly, esthetic problems [72]. Surgical treatment consists of ligation and total excision of the aneurysm [73]. Ekim et al., [74] suggest surgery in all cases to prevent possible complications.

However, in some cases, endovascular methods can be used, like foam, laser or radiofrequency sclerotherapy [75]. In the case of patients who present superficial venous thrombosis above the knee or deep venous thrombosis at any location, it is important to treat with anticoagulants for 3-6 months in patients with normal thrombophilic profiles, otherwise the anticoagulant is prescribed indefinitely. In the presented case, there is no doubt that the chosen surgical treatment is adequate and the treatment with anticoagulants due to the presence of deep thrombosis for a period of three months is acceptable.

The results of the treatment of these types of pathologies are excellent as long as they are not associated with other vascular malformations or pathologies; there are no reports of mortality in superficial VA surgical intervention in the lower extremities and the morbidity is the same as any venous surgical procedure [76].

All our cases, were treated surgically, because in the majority of cases were symptomatic, and the rest of patients preferred surgical treatment because cosmetic reasons or fear to some complication appeared. We preferred surgical approach instead of endovascular procedures because the characteristic and location of the VA.

The diagnosis was supported by DUS and no other studies were required. There was no complication and the outcome was excellent.

## Conclusion

Primary venous aneurysms are not rare, but most attention has been paid to deep venous aneurysm. We must think that primary VA is not a varicose vein. The diagnosis is made by a clinical history and physical examination and corroborated with vascular ultrasound and in selected cases CAT scan or MRI are indicated. Surgery is the best therapeutic strategy considering their potential morbidity and mortality.

## References

1. Lee BB, Laredo J, Lee TS, Huh S, Neville R (2007) Terminology and classification of congenital vascular malformations. *Phlebology* 22: 249-252.
2. Belov ST (1990) Classification of congenital vascular defects. *Int Angiol* 9: 141-146.
3. Lee BB, Baumgartner I, Berlien P, Bianchini G, Burrows P, et al. (2015) Diagnosis and Treatment of Venous Malformations. Consensus Document of the International Union of Phlebology (IUP): updated 2013. *Int Angiol* 34: 97-149.
4. Lee BB, Antignani PL, Baraldini V, Baumgartner I, Berlien P, et al. (2015) ISVI-IUA consensus document diagnostic guidelines on vascular anomalies: vascular malformations and hemangiomas. *Int Angiol* 34: 333-374.
5. Caggiati A, Bergan JJ, Glovickzi P, Eklof B, Allegra C, et al. (2005) Nomenclature of the veins of the lower limb: extensions, refinements, and clinical applications. *J Vasc Surg* 41: 719-724.
6. Lee BB (2015) New classification of congenital vascular malformations (CVMs). *Reviews in Vascular Medicine* 3: 1-5.
7. Lee BB (2015) All congenital vascular malformations should belong to one of two types: "truncular" or "extratruncular", as different as apples and oranges! *Phlebological Review* 1: 1-3.
8. Zamboni P, Cossu A, Carpanese L, Simonetti G, Massarelli G, et al. (1990) The So-Called Venous Aneurysms. *Phlebology* 5: 45-50.
9. CL (1994) *Curchill's Medical Illustrated Dictionary*. Churchill Livingstone, London, United Kingdom.
10. Rodriguez HE, Pearce WH (2009) The management of venous aneurysms. (eds.) Glovicki P, Dalsing MC, Eklof B, Moneta GL, Wakefield TW, *Handbook of venous disorders*. London: Hodder Arnold Pg no: 604-616.
11. Hilscher WM (1995) Zur Frage der venösen Aneurysmen. *Fortscher Röntgenstr* 82: 244-247.
12. Mateo AM, Mateo Martínez M (1997) *Aneurismas venosos*. (eds.) Estevan Solano JM, *Tratado de aneurismas*. Barcelona: Uriach Pg no: 589-597.
13. Van Der Stricht J (1988) Classification of vascular malformations. *Phlebology: The Journal of Venous Disease* 3: 203-206.
14. Belov ST (1989) Classification, terminology, and nosology of congenital vascular defects. (eds.) Belov ST, Loose DA, Weber J, *Vascular Malformations*. Reinbek, Germany: Einhorn-Press 25: 30.
15. Belov St (1993) Anatomopathological classification of congenital vascular defects. *Semin Vasc Surg* 6: 219-224.
16. Mattassi R, Loose DA, Vaghi M (2009) *Hemangiomas and Vascular Malformations: An Atlas of Diagnosis and Treatment*. Springer Verlag Mailand Pg no: 336.
17. [www.issva.org/classification](http://www.issva.org/classification).

18. Wassef M, Blei F, Adams D, Alomari A, Baselga E, et al. (2015) Vascular Anomalies Classification: Recommendations From the International Society for the Study of Vascular Anomalies. *Pediatrics* 136: 203-214.
19. Harris RI (1928) Congenital venous cyst of the mediastinum. *Ann Surg* 88: 953-956.
20. Schild H, Berg ST, Weber W. (1992) Das Veneaneurysma. *Akt Radiol* 2: 75-80.
21. Gillespie DL, Villavicencio JL, Gallagher C, Chang A, Hamelink JK, et al. (1997) Presentation and management of venous aneurysms. *J Vasc Surg* 26: 845-852.
22. Rodriguez HE, Pearce WH (2009) The management of venous aneurysm. (eds.) Glovicki P, Dalsing MC, Eklof BG, Handbook of venous disorders. London: Hodder Arnold Pg no: 604-616.
23. McDevitt DT, Lohr JM, Martin KD, Welling RE, Sampson MG (1993) Bilateral popliteal vein aneurysms. *Ann Vasc Surg* 7: 282-286.
24. Hamper UM, DeJong MR, Scoutt LM (2007) Ultrasound evaluation of the lower extremity veins. *Radiol Clin North Am* 45: 525-548.
25. Sessa C, Perrin M, Nicolini P (2005) Anévrismes veineux. *EMC Chirurgie* 2: 317-331.
26. Arai F, Hirao A, Ohmura M, Sato H, Matsuoka S, et al. (2004) Tie2/angiopoietin-1 signaling regulates hematopoietic stem cell quiescence in the bone marrow niche. *Cell* 118: 149-161.
27. De Palma M, Venneri MA, Galli R, Sergi L, Politi LS, et al. (2005) Tie2 identifies a hematopoietic lineage of proangiogenic monocytes required for tumor vessel formation and a mesenchymal population of pericyte progenitors. *Cancer Cell* 8: 211-216.
28. Davis S, Aldrich TH, Jones PF, Acheson A, Compton DL, et al. (1996) Isolation of angiopoietin-1, a ligand for the TIE2 receptor, by secretion-trap expression cloning. *Cell* 87: 1161-1169.
29. Suri C, Jones PF, Patan S, Bartunkova S, Maisonpierre PC, et al. (1996) Requisite role of angiopoietin-1, a ligand for the TIE2 receptor, during embryonic angiogenesis. *Cell* 87: 1171-1180.
30. Kim I, Kim HG, So JN, Kim JH, Kwak HJ, et al. (2000) Angiopoietin-1 regulates endothelial cell survival through the phosphatidylinositol 3'-Kinase/Akt signal transduction pathway. *Circ Res* 86: 24-29.
31. Irwin C, Synn A, Kraiss L, Zhang Q, Griffen MM, et al. (2008) Metalloproteinase expression in venous aneurysms. *J Vasc Surg* 48: 1278-1285.
32. SCHATZ IJ, FINE G (1996) Venous aneurysms. *N Engl J Med* 266: 1310-1312.
33. Lev M, Saphir O (1951) Endophlebohypertrophy and Endophleboscclerosis II. The external and common iliac veins. *Arch J Pathol* 51: 401-411.
34. Lev M, Saphir O (1951) Endophlebohypertrophy and Endophleboscclerosis. I. The Popliteal Vein. *Arch J Pathol* 51: 154-178.
35. Gruber W (1875) Phlebektasie unter der form eines varix von enormer grosse in vereingungswinkel der vena jugularis interna and und subclavia. *Arch Path Anat* 65: 227-229.
36. de Oliveira Góes Junior AM, Monteiro Franco RM, de Campos Vieira Abib S (2014) Internal Jugular Vein Aneurysm Presenting after Emesis Episode. *Angiol* 2: 130.
37. Andreev A, Petkov D, Kavarakov T, Penkov P (1998) Jugular venous aneurysms: When and how to operate. *Int Angiol* 17: 272-275.
38. Sommer L, Forte V (2001) Congenital venous aneurysms of the internal jugular vein in a child. *J Otolaryngol* 30: 126-128.
39. Indudharan R, Quah BS, Shuaib IL (1999) Internal jugular phlebectasia-an unusual case of neck swelling. *Ann Trop Paediatr* 19: 105-108.
40. Kirmani S, Rashid M, Ali I, Badar F (2011) External jugular vein aneurysm: a rare cause of neck swelling. *J Ultrasound Med* 30: 1157-1158.
41. Al-Shaikhi A, Kay S, Laberge JM (2003) Laberge External jugular venous aneurysm: an unusual cause of a neck mass in a young child. *J Pediatr Surg* 38: 1557-1559.
42. Lee HY, Yoo SM, Song IS, Yu H, Lee JB (2007) "Sonographic diagnosis of a saccular aneurysm of the internal jugular vein. *J Clin Ultrasound* 35: 94-96.
43. Sander S, Eliçevik M, Unal M, Vural O (1999) Vural Jugular phlebectasia in children: is it rare or ignored?. *J Pediatr Surg* 34: 1829-1832.
44. Rawat NS, Gupta A, Khurana P, Jain S, Trehan N (2008) MSCT angiography diagnosis of thrombosis in external jugular venous aneurysm: case report and review of literature. *Indian Heart J* 60: 52-54.
45. Porcellini M, Selvetella L, Bernardo B, Del Guercio L, Baldassarre M (1996) [Aneurysms of the external jugular vein]. *G Chir* 41: 238-241.
46. Beale TJ, Smedly FH, Knee G (1996) Thrombosis within an external jugular venous aneurysm. *J R Coll Surg Edinb* 41: 181-182.
47. Vematsu N, Okada M (1999) Primary Venous Aneurysms: Case Reports. *Angiology* 50: 239-244.
48. Lubianca-Neto JF, Mauri M, Prati C (1999) Internal Jugular Phlebectasia in Children. *Am J Otolaryngol* 20: 415-418.
49. Jianhong L, Xuewu J, Tingze H (2006) Surgical treatment of jugular vein phlebectasia in children. *Am J Surg* 192: 286-290.
50. Jianhong L, Xuewu J, Tingze H (2005) Congenital jugular vein phlebectasia. *Am J Otolaryngol* 26: 172-174.
51. Faraj W, Selmo F, Hindi M, Haddad F, Khalil I (2007) Cephalic vein aneurysm. *Ann Vasc Surg* 21: 804-806.
52. Tahata T, Kusuhara K, Johno H, Okamoto K (2001) Venous Aneurysms of the upper extremity. A case report. *Angiology* 53: 479-481.
53. Schellhammer F, Wobker G, Turowski B (2005) Asymptomatic aneurysm of the subclavian vein. *Acta Radiol* 46: 366-367.
54. Wallace JR, Baril DT, Chaer RA (2013) Upper extremity venous aneurysm as a source of pulmonary emboli. *Ann Vasc Surg* 27: 240.
55. Pedersen G, Laxdal E, Amundsen SR, Dregelid E, Jonung T, et al. (2005) Aneurysm of the subclavian vein. *EJVES Extra* 10: 89-91.
56. McCready RA, Bryant MA, Divelbiss JL, Chess BA (2007) Subclavian venous aneurysm: case report and review of the literature. *J Vasc Surg* 45: 1080-1082.
57. Dubois J, Soulez G, Oliva VL, Berthiaume MJ, Lapierre C, et al. (2001) Soft-tissue venous malformations in adult patients: Imaging and therapeutic issues. *Radiographics* 21: 1519-1531.
58. Paltiel HJ, Burrows PE, Kozakewich HP, Zurakowski D, Mulliken JB (2000) Soft-tissue vascular anomalies: Utility of US for diagnosis. *Radiology* 214: 747-754.
59. Gabrielli R, Rosati MS, Siani A, Irace L (2012) Management of symptomatic venous aneurysm. *Sci World J* 2012: 386478.
60. Seo SH, Kim MB, Kwon KS, Kim CW, Oh CK (2008) Primary venous aneurysms of the superficial venous system. *Angiology* 59: 593-598.
61. Pascarella L, Al-Tuwaijri, Bergan JJ, Mekenas LM (2005) Lower extremity superficial venous aneurysms. *Ann Vasc Surg* 19: 69-73.
62. Labropoulos N, Volteas SK, Giannoukas AD, Touloupakis E, Delis K, et al. (1996) Asymptomatic popliteal vein aneurysms. *Vasc Surg* 30: 453-457.

63. Wolosker N, Zerati AE, Nishinari K, de Melo Galvão Filho M, Wolosker AM (2004) Aneurysm of superior mesenteric vein: case report with 5-year follow-up and review of the literature. *J Vasc Surg* 39: 459-461.
64. Watanabe A, Kusajima K, Aisaka N, Sugawara H, Tsunematsu K (1998) Idiopathic saccular azygos vein aneurysm. *Ann Thorac Surg* 65: 1459-1461.
65. Hermans C, Dessomme B, Lambert C, Deneys V (2006) Venous malformations and coagulopathy. *Ann Chir Plast Esthet* 51: 388-393.
66. Redondo P, Aguado L, Marquina M, Paramo JA, Sierra A, et al. (2010) Angiogenic and prothrombotic markers in extensive slow-flow vascular malformations: implications for antiangiogenic/antithrombotic strategies. *Br J Dermatol* 162: 350-356.
67. Domp Martin A, Acher A, Thibon P, Tourbach S, Hermans C, et al. (2008) Association of localized intravascular coagulopathy with venous malformations. *Arch Dermatol* 144: 873-877.
68. Mazoyer E, Enjolras O, Bisdorff A, Perdu J, Wassef M, et al. (2008) Coagulation disorders in patients with venous malformation of limbs and trunk: a study in 118 patients. *Arch Dermatol* 144: 861-867.
69. Hein KD, Mulliken JB, Kozakewich HP, Upton J, Burrows PE, et al. (2002) Venous malformations of skeletal muscle. *Plast Reconstr Surg* 110: 1625-1635.
70. Enjolras O, Wassef M, Mazoyer E, Frieden IJ, Rieu PN, et al. (1997) Infants with Kasabach-Merritt syndrome do not have "true" hemangiomas. *J Pediatr* 130: 631-640.
71. Mazoyer E, Enjolras O, Laurian C, Houdart E, Drouet L (2002) Coagulation abnormalities associated with extensive venous malformations of the limbs: differentiation from Kasabach-Merritt syndrome. *Clin Lab Haematol* 24: 243-251.
72. Sessa C, Nicolini P, Perrin M, Farah I, Magne JL, et al. (2000) Management of symptomatic and asymptomatic popliteal venous aneurysms: a retrospective analysis of 25 patients and review of the literature. *J Vasc Surg* 32: 902-912.
73. Friedman SG, Krishnasastri KV, Doscher W, Deckoff SL (1990) Primary venous aneurysms. *Surgery* 108: 92-95.
74. Ekim H, Kutay V, Tuncer M, Gultekin U (2004) Management of primary venous aneurysms. *Saudi Med J* 25: 303-307.
75. Lee BB (2013) Endovascular management of the Congenital Vascular Malformation (CVM) is not a panacea. Editorial. *Damar Cer Derg* 22: 1-3.
76. Roh YN, Do YS, Park KB, Park HS, Kim YW, et al. (2012) The results of surgical treatment for patients with venous malformations. *Ann Vasc Surg* 26: 665-673.





Journal of Anesthesia & Clinical Care  
Journal of Addiction & Addictive Disorders  
Advances in Microbiology Research  
Advances in Industrial Biotechnology  
Journal of Agronomy & Agricultural Science  
Journal of AIDS Clinical Research & STDs  
Journal of Alcoholism, Drug Abuse & Substance Dependence  
Journal of Allergy Disorders & Therapy  
Journal of Alternative, Complementary & Integrative Medicine  
Journal of Alzheimer's & Neurodegenerative Diseases  
Journal of Angiology & Vascular Surgery  
Journal of Animal Research & Veterinary Science  
Archives of Zoological Studies  
Archives of Urology  
Journal of Atmospheric & Earth-Sciences  
Journal of Aquaculture & Fisheries  
Journal of Biotech Research & Biochemistry  
Journal of Brain & Neuroscience Research  
Journal of Cancer Biology & Treatment  
Journal of Cardiology: Study & Research  
Journal of Cell Biology & Cell Metabolism  
Journal of Clinical Dermatology & Therapy  
Journal of Clinical Immunology & Immunotherapy  
Journal of Clinical Studies & Medical Case Reports  
Journal of Community Medicine & Public Health Care  
Current Trends: Medical & Biological Engineering  
Journal of Cytology & Tissue Biology  
Journal of Dentistry: Oral Health & Cosmesis  
Journal of Diabetes & Metabolic Disorders  
Journal of Dairy Research & Technology  
Journal of Emergency Medicine Trauma & Surgical Care  
Journal of Environmental Science: Current Research  
Journal of Food Science & Nutrition  
Journal of Forensic, Legal & Investigative Sciences  
Journal of Gastroenterology & Hepatology Research  
Journal of Gerontology & Geriatric Medicine  
Journal of Genetics & Genomic Sciences  
Journal of Hematology, Blood Transfusion & Disorders  
Journal of Human Endocrinology  
Journal of Hospice & Palliative Medical Care  
Journal of Internal Medicine & Primary Healthcare  
Journal of Infectious & Non Infectious Diseases  
Journal of Light & Laser: Current Trends  
Journal of Modern Chemical Sciences  
Journal of Medicine: Study & Research  
Journal of Nanotechnology: Nanomedicine & Nanobiotechnology  
Journal of Neonatology & Clinical Pediatrics  
Journal of Nephrology & Renal Therapy  
Journal of Non Invasive Vascular Investigation  
Journal of Nuclear Medicine, Radiology & Radiation Therapy  
Journal of Obesity & Weight Loss  
Journal of Orthopedic Research & Physiotherapy  
Journal of Otolaryngology, Head & Neck Surgery  
Journal of Protein Research & Bioinformatics  
Journal of Pathology Clinical & Medical Research  
Journal of Pharmacology, Pharmaceutics & Pharmacovigilance  
Journal of Physical Medicine, Rehabilitation & Disabilities  
Journal of Plant Science: Current Research  
Journal of Psychiatry, Depression & Anxiety  
Journal of Pulmonary Medicine & Respiratory Research  
Journal of Practical & Professional Nursing  
Journal of Reproductive Medicine, Gynaecology & Obstetrics  
Journal of Stem Cells Research, Development & Therapy  
Journal of Surgery: Current Trends & Innovations  
Journal of Toxicology: Current Research  
Journal of Translational Science and Research  
Trends in Anatomy & Physiology  
Journal of Vaccines Research & Vaccination  
Journal of Virology & Antivirals  
Archives of Surgery and Surgical Education  
Sports Medicine and Injury Care Journal  
International Journal of Case Reports and Therapeutic Studies

Submit Your Manuscript: <http://www.heraldopenaccess.us/Online-Submission.php>