

## Original Research

### Venous Pressure Gradient: It's Role in Diagnosis and Treatment of Steno-Obstructions of Deep Venous System

Sergio Petronelli<sup>1</sup>, Maria Teresa Zurlo<sup>1</sup> and Giuseppe Guglielmi<sup>2,3</sup>

<sup>1</sup>Department of Interventional Radiology and Vascular Surgery, Surgical Department, "Miulli" General Hospital, Acquaviva delle Fonti, BA, Italy

<sup>2</sup>Department of Radiology, University of Foggia, Viale Luigi Pinto, Foggia, Italy

<sup>3</sup>Department of Radiology, Scientific Institute Hospital "Casa Sollievo della Sofferenza", viale Cappuccini, San Giovanni Rotondo, FG, Italy

#### Abstract

**Objectives:** To show a simple endovascular technique both to do the diagnosis of the steno-obstructions of caval iliac femoral veins, in chronic venous hypertensions and to evaluate the results of angioplasty and stent treatment.

**Materials and methods:** A total of 90 Patients (Pt) in CEAP clinical class 3-6 (according to CEAP classification-clinical, etiologic, anatomic, pathophysiologic for chronic venous disease) were evaluated for steno-obstructions of caval iliac femoral veins with a new technique of measurement of Venous Pressure Gradient (VPG) and with a morphological evaluation of these deep veins; we considered as indicator of venous hypertension a pressure gradient  $\geq 3\text{mmHg}$  /400 Pa.

In the first experience we analyzed 60 Pt; we considered eligible for the treatment of venous iliac Percutaneous Transluminal Angioplasty/Stenting (PTA/Stent). Only the patients with the presence of pressure gradient associated to a morphological stenosis  $>50\%$ , measured through retrograde Digital Phleboscopia (DPH). We named Pt DPH this court of patients.

In the second experience with the remaining 30 patients, we considered the patients with positivity to the pressure gradient are eligible for the treatment. In this case we used a new morphological technique Intra-Venous Ultrasound (IVUS), only to have a few details about neointima (Pt Iv).

Technical success will be considered after the PTA /stent value of VPG is equal to  $0\text{mmHg/Pa}$ . Clinical and Ultrasound (US) evaluation was performed before and after the treatment; in case of stenting we performed Computerized Tomography (CT) evaluation during follow up.

**Results:** We have totally evaluated 90 Pt; in the first experience with

60 consecutive Pt ranked as CEAP III-VI. In 15 Pt we found VPG  $\geq 3\text{mmHg}$  ( $\geq 400\text{ Pa}$ ) and only 5 Pt with stenosis  $\geq 50\%$  by DPH.

In these 5 Pt we performed iliac venous 4 PTA and 1 stenting.

In the second experience with the remaining 30 consecutive Pt ranked as CEAP III-VI. In 6 Pt we found VPG  $\geq 3\text{mmHg}$  ( $\geq 400\text{ Pa}$ ). In all these Pt IVUS confirmed a morphological wall thickening without morphological stenosis to DPH. We performed iliac venous 4 PTA and 2 Stenting.

We obtained the technical success after angioplasty/stenting of iliac vein steno-obstructions in all cases. No other complications is observed during the procedure.

F.W. at 12 months (range: 3-24 months) showed a clinical down-staging in all patients with no occlusion in the site of the treatment.

**Conclusion:** Our endovascular technique allows the measurement of the pressure gradient and the discover of the venous chronic hypertension in caval iliac femoral veins.

The measurement of VPG provides the finding of iliac steno-obstructions without the evidence of stenosis by DPH. Moreover it is possible that the minimal changes in neointima can alter wall characteristics and its capacitance and increase the venous pressure. The VPG equal to  $0\text{mmHg/Pa}$  after iliac venous PTA/stenting together with good clinical outcome could be used to show the effectiveness of the treatment of venous chronic hypertension.

**Keywords:** Angioplasty; Phlebography; Venous pressure

#### Abbreviations

CEAP (Clinic, Etiology, Anatomy and Pathogenesis of chronic venous insufficiency): The CEAP classification system, developed under the auspices of American Venous Forum consists of four components which are the description of clinical disease class (C) based on objective signs - etiology (E), anatomic distribution of reflux and obstruction (A) and pathophysiologic whether related to reflux and/or obstruction (P). CEAP system consists of seven clinical disease categories: asymptomatic limbs (class 0); Pt with telangiectasias (class 1); varicose veins (class 2), Pt with edema (class 3), Pt with skin discolorations but without ulceration (class 4), Pt with ulcers recovered (class 5), Pt with active ulcers (class 6)

VCSS: Venous Clinical Severity Score

DVS: Deep Venous System

CVI: Chronic Venous Insufficiency

CFV: Common Femoral Vein

ECD: Eco-Color Doppler

IVUS : Intra-Venous Ultrasound

VPG: Venus Pressure Gradient

Pt DPH: First cohort of Pt with Digital Phleboscopia

Pt Iv: Second cohort of Pt with IVUS

PTA: Percutaneous Transluminal Angioplasty

US: Ultrasound

CT: Computerized Tomography

DVT: Deep Venous Thrombosis

DPH: Digital Phleboscopia

#### Introduction

The importance of chronic venous hypertension of the Deep Venous System (DVS) has recently been underlined in all clinical classes

\*Corresponding author: Sergio Petronelli, Department of Interventional Radiology and Vascular Surgery, Surgical Department, "Miulli" General Hospital, Acquaviva delle Fonti, BA, Italy, Tel: +39 0803054246; E-mail: spetro@tiscali.it

**Citation:** Petronelli S, Zurlo MT, Guglielmi G (2017) Venous Pressure Gradient: It's Role in Diagnosis and Treatment of Steno-Obstructions of Deep Venous System. J Angiol Vasc Surg 2: 009.

**Received:** May 24, 2017; **Accepted:** September 1, 2017; **Published:** September 19, 2017

(especially CEAP 3-6 [1-2-5]) as a decisive factor in chronic venous insufficiency.

Chronic venous outflow obstructions more than the reflux are important in venous hypertension; it is known that they usually occur months to years after an initial Deep Venous Thrombosis (DVT). In symptomatic patients, recanalisation of thrombotic veins is incomplete and the collateral circulation is inadequate resulting in distal venous hypertension with lower extremity swelling, pain worsened after ambulation, venous ulcers and others clinical manifestations of post thrombotic syndrome. Although venous outflow obstructions of the lower extremity may involve the entire venous system, ilio caval venous steno-obstructions, more than peripheral obstructions, play an important role in determining the most severe symptoms of venous insufficiency [1-6].

Related to diagnostic difficulties, steno-obstructions have been ignored whereas emphasis was placed only on reflux [3]. Pelvic Eco Color Doppler examination (ECD) indeed does not provide us the possibility to evaluate exactly the anatomy of iliac veins. On the other hand, second-level imaging examinations, such as Angiography Computed Tomography (Angio-CT) or Magnetic Resonance Imaging (MRI) is too expensive and do not provide hemodynamic data.

Moreover in the last decade a few authors describe the much broadened disease profile that emerged with the use of IVUS for diagnosis, finding the incidence of no thrombotic iliac vein outflow obstructions to be very high in symptomatic CVI cases; it has been known that the etiology of venous steno-obstructions can be primary (non-thrombotic) or secondary (post-thrombotic) with equal prevalence estimated in patients with chronic venous disease [2-7]. It was already known that primary forms are related to compression of the left iliac common vein, anatomically near to the hypogastric artery bifurcation, with presence of webs or membranes resulting from traumatic injury caused by pulsations of the artery [7,8]. Moreover, with IVUS has emerged that the primary disease is dominant but not exclusive to left lower limb; so any patient should be excluded from consideration of these lesions based on age, sex, bilaterality, or involvement of the right side [9].

A combination of reflux and obstruction is commonly present in either aetiology [10]. Regarding the treatment of limbs with CVI, while the interventions on the superficial venous system and perforator veins is more or less effective both with surgical and innovative technique, that on deep venous system, has pointed on the treatment of the deep reflux even if with poor results. Moreover, in the past open surgical treatment of iliac steno-obstructions failed for the low success rates and for the high invasiveness.

Recently, the treatment options on deep venous system have changed dramatically with a great interest for chronic deep venous iliac steno-obstructions. Endovascular treatment involving the use of iliac venous PTA and stenting has become gold standard treatment [1-11].

But in literature there is not a universal and recognized parameter able to select patients with caval iliac femoral out-flow obstructions responsible of venous hypertension and CVI; the limitations of diagnostic tests are related to the absence of a uniform definition of hemodynamically significant venous stenosis. Currently there is not a direct correlation between the morphological degree of stenosis and the venous pressure gradient. Small changes in the vessel wall, for example as outcomes of previous inflammation, could provide

compliance's reduction and as a consequence significant hypertension and CVI. The absence of a "gold standard" is a major obstacle to the evaluation of the chronic outflow obstructions, the selection of the limb to be treated and the monitoring of technical success of endovascular treatment with PTA and stenting [1].

We would like to find a simple and standardized endovascular technique to assess caval-iliac-femoral out-flow obstructions using hemodynamic rather than morphological criteria.

The aim of this report is to demonstrate the use of venous pressure gradient in the assessment of iliac-femoral-cava venous hypertension so as to provide both a better selection of patients for endovascular treatment and a standard evaluation of the treatment's effectiveness.

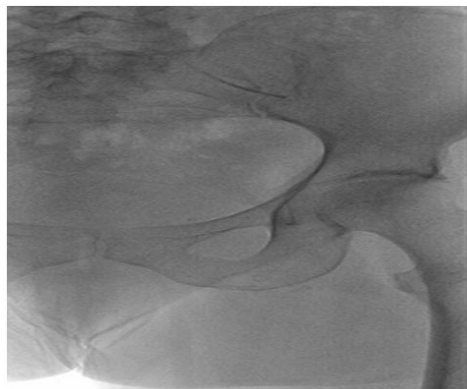
## Materials and Methods

From 2011 to 2013 a total number of 90 patient with chronic venous disease in CEAP III-IV (patients: 68% female; 32% male with female-male ratio 2.1:1; median age of 52 years, range 24-70) were evaluated for the presence of venous outflow steno-obstructions of iliac-femoral-cava system with a new technique of measurement of Venous Pressure Gradient (VPG) and with morphological evaluation of these deep veins. All patients signed an informed consent to the execution of the examination. Before treatment, every patient was evaluated with venous ECD and from a clinical point of view using CEAP classification; In order to evaluate venous hypertension we used a pressure gradient between the femoral-iliac venous axis and iliac-caval venous axis. The procedure was performed in angiography suite with patient in supine position in local anaesthesia and intravenous sedation; we have usually used a catheter multipurpose 5F with radiopac tip and 90 cm in length (COOK) connected to a membrane pressure transducer (CODAN) with a range of 0 to 50 mmHg and a digital monitor.

Following scientific literature data and our previous clinical experience, we considered as normal a pressure gradient value equal to zero. We considered as an indicator of venous hypertension a pressure gradient  $\geq 3$  mmHg/400 Pa.

Our technique consists of a contralateral inguinal puncture of the side to be evaluated [12]. After skin disinfection of the groin we proceed with a puncture and catheterise of Common Femoral Vein (CFV) using a 6Fr introducer. After iliac cross-over, using a stiff guidewire 0,35 of 260 cm in length and a multipurpose catheter 5Fr of 90 cm in length we catheterize the CFV of the other side and we proceed with the measurement of the venous gradient between femoral-iliac veins and caval veins and then of the side of the puncture (Figure 1). For the measurement of the venous pressure we put the transducer at the cardiac level and after zero we connect it through a catheter connection to the vein; by moving the catheter we measure the pressure at different points along the femoral – iliac and caval venous axis. We carry out measurements with the patient at the same stage of breathing. Then we measure the gradient between the highest value and the lowest measured value.

In the first experience (Pt DPh) with 60 Pt we performed retrograde DPh of the femoral iliac caval venous system to confirm the catheter tip position and to have a morphological evaluation of the venous axis; we used 1-2 injections of approx 20ml of visipaque 270 contrast solution with Medrad Mark V digital automatic injector using Philip Allura X angiographic machine; the use of digital phleboscopy reduces radiations to the patient. In this court of patients we



**Figure 1:** Phleboscopic image of technique.

Catheterisation of left Common Femoral Vein (CFV) and iliac vein after contralateral inguinal puncture: selective catheterisation of common left femoral vein and pressure measurement (mmHg / Pa).

considered for treatment the presence of a stenosis of a diameter vessel reduction  $\geq 50\%$  and a pressure gradient  $\geq 3\text{mmHg}/400\text{Pa}$ .

In the second experience (Pt Iv) with 30 Pt we only considered for treatment the presence of a pressure gradient  $\geq 3\text{mmHg}/400\text{Pa}$ ; in these cases we performed IVUS, even if there was not a stenosis with DPh so as to evaluate changes in vein wall. Technical success will be considered if VPG is equal to zero after PTA/stent treatment.

In case of angioplasty, we used balloon FOX ABBOTT with diameter 9-12 mm and pressure 8-10 atmosphere. In case of stent, we used stent SMART CORDIS (14x80mm).

Clinical and ecodoppler follow-up was carried out at 12 months (range: 3-24 months) in all treated patients. Clinical outcome was evaluated with Venous Clinical Severity Score (VCSS) before and after treatment.

The team involved in the present study consisted of a vascular surgeon and an interventional radiologist with experience in venous disease and endovascular techniques on the superficial and deep venous system.

## Results

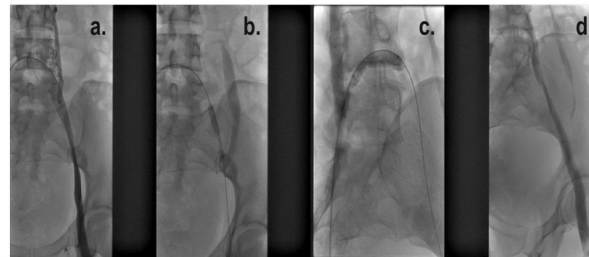
In our study we had included a total number of 90 Pt CEAP III-VI of whom 21 had a VPG  $\geq 3\text{mmHg}/400\text{Pa}$  (23% of all pt) (Table 1).

VPG measurement	Positive >3mmHg	Negative	Not Treated	Treated
n.60 (Ph)	15	45	10	5
n.30 (Iv)	6	24	0	6
Total n.90	21	69	10	11

**Table 1:** Pt undergone VPG evaluation.

In our first experience with a number of 60 Pt (Pt Ph) we carried out the evaluation of VPG and morphological parameter of steno-obstruction with DPh: we had in 15 procedures VPG  $\geq 3\text{mmHg}/400\text{Pa}$  and only in 5 cases of these 15 procedures we had a stenosis  $\geq 50\%$ . We performed 4 PTA and 1 Stent. In conclusion, we performed angioplasty/stenting treatment in 5 cases classified as CEAP III-VI.

About 5 cases were treated with angioplasty/stenting: three of all regarding iliac left veins alone, one regarding left iliac and carrefour iliac vein and one stenting left iliac vein (Figure 2) (Table 2).



**Figure 2:** Phleboscopic steno-obstruction images of carrefour and left common iliac vein a) the steno-obstruction b-c) the balloon angioplasty of these segments d) the phleboscopic final control post-angioplasty.

Phpt	PTA	PTA
Left iliac vein	3	3
Left iliac vein +Iliac carrefour	1	1
Total	4	4

**Table 2:** Procedures in patients with positive VPG and morphological phleboscopic stenosis divided for localization of pathology and performed procedures.

In second experience with a number of 30 Pt (Pt Iv), we carried out the evaluation of pressure gradient without morphological stenosis with DPh. In 6 procedures VPG was  $\geq 3\text{mmHg}/400\text{Pa}$  and in all these cases IVUS confirmed thickening of the venous wall. We performed 4 angioplasty and 2 stenting.

In conclusion, we performed angioplasty/stenting treatment in 6 cases classified as CEAP III-VI.

About 6 cases treated with angioplasty/stenting: two of all regarding iliac left veins alone, one left femoral and left iliac vein, one right iliac vein, one stenting of left iliac vein after unsuccessful angioplasty and one stenting for right iliac vein occlusion (Figures 3,4) (Table 3).

Iv Pz	PTA	STENT
Left iliac vein	2	1
Left iliac vein + femoral vein	1	
Right iliac vein	1	1
Total	4	2

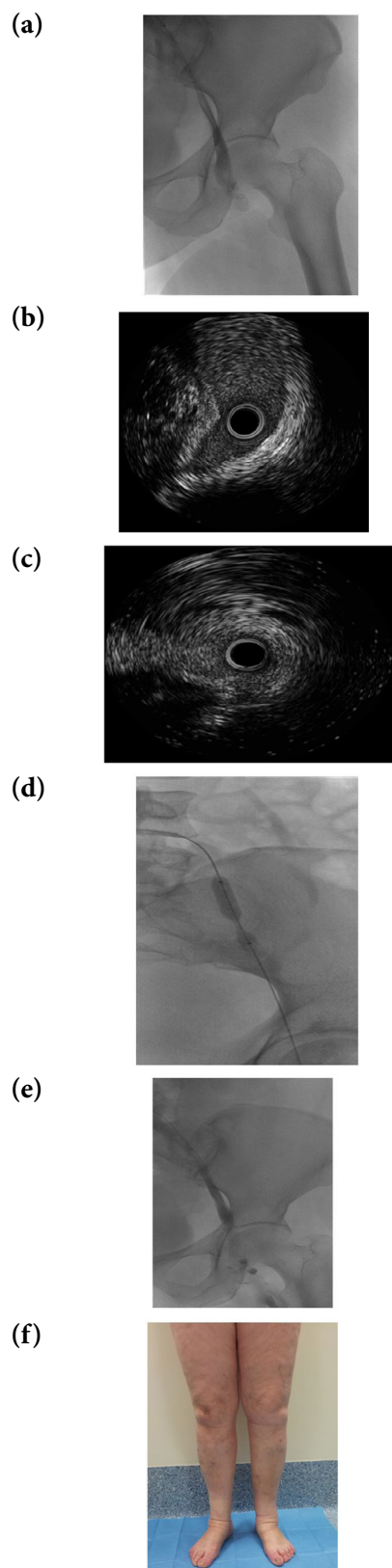
**Table 3:** Procedure in patients with VPG positive and IVUS positive divided for localization of pathology and performed procedures.

Technical success of angioplasty/stenting of iliac vein steno-obstructions with resolution pressure gradient ( $P=0\text{mmHg}$ ) was equal to 100% of cases. No early and later complications occurred in our experience.

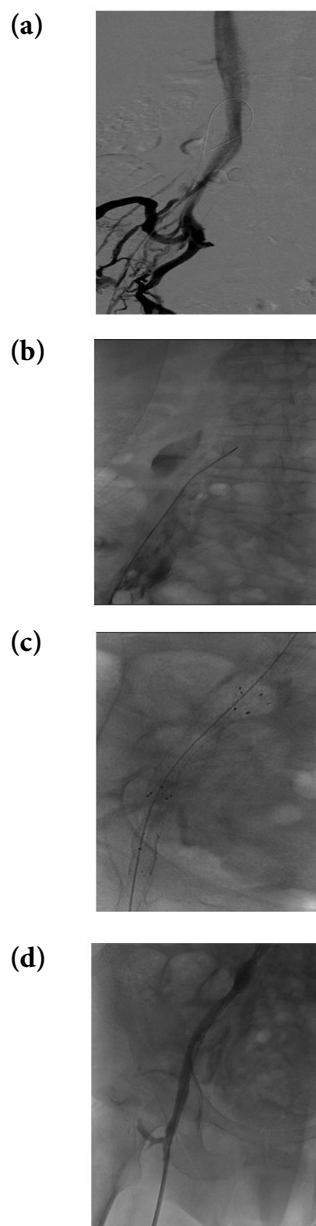
The early clinical improvement after angioplasty/stenting of iliac vein was demonstrated by reduction of edema and symptoms of heaviness and pain on the inferior limbs suddenly after the treatment; all Pt had a clinical down staging during follow-up. ECD follow-up demonstrated no occlusions and computed tomography follow-up showed pervious stents without evidence re-stenosis or fractures.

## Discussion

Ilio-caval venous steno-obstructions have an important role in symptomatic chronic venous insufficiency and more than venous reflux is the cause of the most several symptoms of venous disease. New studies seem to prove that iliac vein obstructions are more important than venous distal vessels obstructions in determining the vast



**Figure 3:** Pt with VPG > 3 mmHg/400 Pa after treatment left limb (Pt Iv) a) Phleboscopic image without stenosis of external left iliac vein b) IVUS (Intravenous Ultrasound) image it shows is pessimist the vein wall before treatment c) IVUS image its shows vein wall after treatment d) PTA (percutaneous transluminal angioplasty) of iliac vein e) phleboscopic image after PTA with VPG=0 f) clinical improvement of edema of the left leg.



**Figure 4:** Pt with phlebography images with right iliac vein obstruction and collateral pathway and VPG > 3 mmHg (Pt Ph) a) Phlebography image it shows right iliac vein obstruction and collateral pathway b) catheterism VPG > 3 mmHg after the guide crossing c) primary stenting of iliac vein d) Phleboscopic re-canalization of iliac vein and disappearance of collateral pathway and catheterism VPG = 0 mmHg.

majority of symptoms of venous disease [1,6,13]. In the past, clinical attention was focused only on venous reflux, due to the difficult diagnostic recognition of the hemodynamic critical venous obstructions [3].

Before the development of PTA/Stenting, venous iliac obstructions were corrected by surgical bypass reconstruction; these major surgical procedure usually had low technical success, high rate of complications; for these reasons only patients with severe CVI were selected for interventions; The indications for surgical treatment of Palma by-pass was a mean resting pressure difference of >2mmHg between the right and the left common femoral veins [14].

Recently endovascular treatment involving the use of PTA and

stenting has become gold standard treatment of caval iliac and femoral outflow obstructions because it is a minimally invasive approach, has a high technical success rate and an acceptable complication profile [1-11].

Iliac vein PTA/Stenting is an extension of arterial endovascular technology; the two share some technical similarities and much of the hardware, however the indications for and the purpose of iliac vein PTA/Stenting are fundamentally different.

Current diagnostic modalities do not allow a definitive assessment of critic hemodynamic venous obstructions to be treated. The diagnosis is based both on clinical signs and symptoms and on radiological assessment of morphological venous outflow such as trans-femoral phlebography, Intravascular Ultrasound (IVUS), CT and MR venography [5,11,13].

Moreover, does not help the history of a previous thrombosis to selecting patients; from an etiological point of view, the incidence of primary form is higher than the secondary type. In our series, only 3 Pt were previously diagnosed with venous deep thrombosis.

On the base of previous results published in literature, the incidence of outflow steno-obstructions is higher in the most several clinical classes (CEAP 5-6) with 37% of ilio-caval steno-obstructions =50% and 23% of cases greater than 80%, on average [5]. Only in case of obstructions greater than 80% the association with reflux, female gender and history of deep vein thrombosis was significant and only in these cases authors suggest the performance of CT or MR venography routinely.

Imaging diagnosis cannot be related to US alone. The visualization of the iliac veins in pelvis, in fact, could be difficult due to pelvic organs and bowel gas. In addition, Doppler wave forms in the common femoral veins can display normal spontaneous flow and respiratory variation due to large collateral vessels around the site of proximal obstruction [15]. Nowadays, there is not a gold standard for selection of patients who need treatment of iliac outflow obstruction; on one hand the anterograde phlebography can result in false negative images, on the other hand IVUS is very helpful but could be used only in a small number of patients [15].

Recently, the introduction of IVUS allowed advances in knowledge of venous stenosis because it could provide us the possibility to evaluate intra-luminal details such as wall thickness and neo-intimal hyperplasia in patients with venous steno-obstructions, usually underestimated by phlebography [11]. It is possible that this intra-luminal alterations resulting from inflammatory processes are correlated with increase in pressure gradient, such as in other venous districts (e.g., superior vena cava syndrome, stenosis in A-V fistulas, etc.) [16-18]. From this consideration it is clear that not always a venous hypertension caused by reduction of wall compliance may be morphologically related to a critical stenosis.

On the other hand, the venous hypertension has been correlated with clinical manifestations of chronic venous disease (edema, erythema, ulcer, dyschromia) determining inflammation. As a consequence, flogosis cause vein wall changes, increasing venous hypertension [17].

In our study, we found that the parameter of iliac-femoral pressure gradient could be correlated with venous hypertension. Our data show, in fact, that the pressure gradient equal to zero has a high

sensitivity for the absence of venous hypertension. Starting from this parameter, despite the small number of cases (21/90 cases), we believe that an increase of pressure gradient  $\geq 3\text{mmHg}/400\text{ Pa}$  could be indicative of venous hypertension. In literature there are not studies about pressure gradient along venous stenosis. Few authors described an increase of pressure in the femoral vein before and after the exercise or compared to the opposite side; but this pressure value concern the whole leg instead of segmental venous axis [14,15,19].

Moreover the use of gradient pressure is easy method because it is a scalar magnitude that does not suffer from other variables because it is a pressure difference.

Furthermore, we found that pressure gradients  $\geq 3\text{mmHg}/400\text{Pa}$  is also important when morphological images do not show signs of venous stenosis because, after treatment of axis femoral iliac involved, the pressure gradient become normal.

More evidences in the literature showed that mild degrees of stenosis could be responsible of venous hypertension and, as a consequence, of chronic venous disease [1,20-22].

For this reason we believe that this parameter can be used as a predictor of chronic venous hypertension even in absence of evident morphological stenosis [18]. In our second experience we use only VPG for the evaluation of patients. Following this parameter, we increased the number of patients treated (6/30 vs 5/60 treated in the first experience). The measurement of VPG, in our experience, is a more sensible parameter in the diagnosis of venous steno-obstructions confirmed by IVUS. In fact, when we used as parameter to treat the presence of morphological stenosis with DPh, we missed 47% of patients with  $\text{VPG} \geq 3$  (Table 4).

Patient with $\text{VPG} > 3\text{mmHg}$	Without endovascular treatment	Endovascular treatment
21	10* / 21 (47%)	(5*+6**) 11/21 (52%)

**Table 4:** Pt with  $\text{VPG} > 3\text{mmHg}/400\text{Pa}$  and % pt with and without treatment. \*ptPh \*\*pt Iv

We found 23% of Pt CEAP III-VI with  $\text{VPG} \geq 3$  in front of a higher rate of patient with stenosis from other authors (5). We used a value of  $\text{VPG} \geq 3\text{mmHg}/400\text{ Pa}$  in spite of a value hypertension of 2mmHG reported in literature. It is possible that a selection of patients in CEAP V-VI might increase the number of patients.

In patients without morphological evidence of steno-obstructions the pressure gradient normalization post-PTA leads necessarily to a further investigations with other techniques such as IVUS before and after dilatation.

## Conclusion

This study allows implementing standardization of a repeatable method to evaluate the pressure gradient of the caval-femoral-iliac axis. For this reason, this technique could be used to diagnose venous hypertension, especially in the more advanced classes (CEAP 3-6). VPG equal to zero after treatment (PTA/Stenting) and clinical down staging (reduction of edema, recovered ulcers) show its importance also in absence of morphological stenosis. On the base of these results, we would expect an increased diagnosis of venous hypertension, in respect of the use of only VPG.

## References

1. Mahnken AH, Thomson K, de Haan M, O'Sullivan GJ (2014) CIRSE Standards of Practice Guidelines on Iliocaval Stenting. *Cardiovasc Intervent Radiol* 37: 889-897.
2. Hartung O, Otero A, Boufi M, De Caridi G, Barthelemy P, et al. (2005) Mid-term results of endovascular treatment for symptomatic chronic non-malignant ilio caval venous occlusive disease. *J Vasc Surg* 42: 1138-1144.
3. Neglén P (2008) Chronic deep venous obstruction: definition, prevalence, diagnosis, management. *Phlebology* 23: 149-157.
4. Titus JM, Moise MA, Bena J, Lyden SP, Clair DG (2011) Iliofemoral stenting for venous occlusive disease. *J Vasc Surg* 53: 706-712.
5. Marston W, Fish D, Unger J, Keagy B (2011) Incidence of and risk factors for ilio caval venous obstruction in patients with active or healed venous leg ulcers. *J Vasc Surg* 53: 1303-1308.
6. Neglén P, Raju S (2002) Proximal lower extremity chronic venous outflow obstruction: recognition and treatment. *Semin Vasc Surg* 15: 57-64.
7. Almeida JJ, Boatright C (2011) Iliocaval stenting for advanced chronic venous disease. *Endovascular Today* 10: 62-64.
8. Kibbe MR, Ujiki M, Goodwin AL, Eskandari M, Yao J, et al. (2004) Iliac vein compression in an asymptomatic patient population. *J Vasc Surg* 39: 937-943.
9. Raju S, Neglén P (2006) High prevalence of nonthrombotic iliac vein lesions in chronic venous disease: a permissive role in pathogenicity. *J Vasc Surg* 44: 136-143.
10. Raju S, Darcey R, Neglén P (2010) Unexpected major role for venous stenting in deep reflux disease. *J Vasc Surg* 51: 401-408.
11. Raju S (2013) Best management options for chronic iliac vein stenosis and occlusion. *J Vasc Surg* 57: 1163-1169.
12. Neglén P (2007) Chronic venous obstruction: diagnostic considerations and therapeutic role of percutaneous iliac stenting. *Vascular* 15: 273-280.
13. Mussa FF, Peden EK, Zhou W, Lin PH, Lumsden AB, et al. (2007) Iliac vein stenting for chronic venous insufficiency. *Tex Heart Inst J* 34: 60-66.
14. Neglén P, Thrasher TL, Raju S (2003) Venous outflow obstruction: An underestimated contributor to chronic venous disease. *J Vasc Surg* 38: 879-885.
15. Bergan JJ, Schmid-Schönbein GW, Smith PD, Nicolaidis AN, Boisseau MR, et al. (2006) Chronic venous disease. *N Engl J Med* 355: 488-498.
16. Costa A, Veneziani A, Vergara C (2005-2006) Modellazione Numerica dei distretti venosi a partire da modelli matematici monodimensionali Tesi di Laurea Facoltà di Ingegneria Biomedica matricola 632389 Politecnico di Milano. 32-49.
17. Raju S (2015) Treatment of iliac-caval outflow obstruction. *Semin Vasc Surg* 28: 47-53.
18. Neglén P, Raju S (1993) Detection of outflow obstruction in Chronic venous insufficiency. *J Vasc Surg* 17: 583-589.
19. Nayak L, Hildebolt CF, Vedantham S (2012) Postthrombotic syndrome: feasibility of a strategy of imaging-guided endovascular intervention. *J Vasc Interv Radiol* 23: 1165-1173.
20. Wen-da W, Yu Z, Yue-Xin C (2016) Stenting for chronic obstructive venous disease: A current comprehensive meta-analysis and systematic review. *Phlebology* 31: 376-389.
21. Alhalbouni S, Hingorani A, Shiferson A, Gopal K, Jung D, et al. (2012) Iliac-femoral venous stenting for lower extremity venous stasis symptoms. *Ann Vasc Surg* 26: 185-189.
22. Petronelli S, Prudenzano R, Mariano L, Violante F (2006) Endovenous laser therapy of the incompetent great saphenous vein. *Radiol Med* 111: 85-92.