

Case Study

Video Dermatoscopy in Lymphoedema - An Additional Tool

Chirra Likhitha Reddy, Ravi Kumar Chittoria*, Abhinav Aggarwal, Saurabh Gupta, Padma Lakshmi Bharathi Mohan, Shijina K and Imran Pathan

Department of Plastic Surgery, Jawaharlal Institute of Postgraduate Medical Education and Research (JIPMER), Pondicherry, India

Abstract

Lymphoedema is a major cause of morbidity which is associated with physical, psychological and social burdens. The affected limb has skin changes that range from pitting edema to fissures which are associated with infection. We would like to present our experience with the use of videodermatoscopy to identify the various skin changes at a magnification which might help us to prevent and treat infections more effectively.

Keywords: Dermatoscopy; Lymphoedema; Videodermatoscopy

Introduction

Videodermatoscopy (VD) is a non-invasive technique in which skin is observed in vivo by a video camera equipped with lenses that allow magnifications ranging from 4x to 1000x. The images obtained are visualized on a high definition monitor and may be stored on a personal computer, in order to identify and compare changes over time [1].

Lymphoedema (primary & secondary) is associated with various secondary skin changes ranging from reversible pitting edema to mossy foot. These skin changes are classified by WHO into 7 stages [2].

According to the Fifth WHO Expert Committee on Filariasis, lymphoedema can be classified as follows:

*Corresponding author: Ravi Kumar Chittoria, Department of Plastic Surgery, Jawaharlal Institute of Postgraduate Medical Education and Research (JIPMER), Pondicherry, India, Tel: +91 9442285670; E-mail: drchittoria@yahoo.com

Citation: Reddy CL, Chittoria RK, Aggarwal A, Gupta S, Mohan PLBM, et al. (2019) Video Dermatoscopy in Lymphoedema - An Additional Tool. J Clin Dermatol Ther 5: 040.

Received: October 29, 2019; **Accepted:** November 11, 2019; **Published:** November 18, 2019

Copyright: © 2019 Reddy CL, et al. This is an open-access article distributed under the terms of the Creative Commons Attribution License, which permits unrestricted use, distribution, and reproduction in any medium, provided the original author and source are credited.

- Grade I lymphoedema: mostly pitting edema; spontaneously reversible on elevation
- Grade II lymphoedema: mostly non-pitting edema; not spontaneously reversible on elevation
- Grade III lymphoedema (elephantiasis): a gross increase in volume in a grade II lymphoedema, with dermatosclerosis and papillomatous lesions

The 7 stages of classification as given below are clinically based [2]:

Stage 1: The feature of stage 1 lymphoedema is:

- Swelling is reversible overnight
- In stage 1 lymphoedema, the swelling increases during the day and disappears overnight

Stage 2: Swelling is not reversible overnight

The main difference between stage 2 lymphoedema and stage 1 is that the swelling does not disappear without lymphoedema management.

Stage 3: Swelling is not reversible overnight. The principal feature of stage 3 lymphoedema is the presence of one or more shallow skin folds

Stage 4: Swelling is not reversible overnight.

The main feature of stage 4 lymphoedema is the presence of knobs lumps, lumps, or protrusions on the skin

Stage 5: Swelling is not reversible overnight.

The presence of one or more deep skin folds is the main feature of stage 5 lymphoedema

Stage 6: Swelling is not reversible overnight. On the surface of the foot (especially the toes), very small elongated or rounded small knobs can be clustered together, giving rise to the peculiar appearance of "mossy foot"

Patients with stage 6 lymphoedema) have acute attacks. Almost all these patients have entry lesions between the toes and bad odour. Wounds in the skin are frequently present.

Stage 7: The features of stage 7 lymphoedema are:

- Swelling is not reversible overnight. The patient is unable to adequately or independently perform routine daily activities such as walking, bathing, cooking, etc.

These skin changes are a result of stagnation of lymph, inflammation leading to fibrosis. This also leads to inability to care for the affected limb leading to a vicious cycle of infection, inflammation and further deterioration of the skin condition.

Emphasis on management of lymphedema is in the treatment and prevention of infection of the limb, the main source of which is the fissures in the skin through which ascending lymphangitis is noticed.

Even though most of the skin changes are visible through the naked eye, videodermatoscopy may help for accurate assessment of the skin changes and possible sites of future infection may be identified earlier due to higher magnification, thus leading to better management of the patient.

Materials and Methods

This is a case report of a 29 year female patient admitted in plastic surgery department in the month of August 2019, with h/o swelling of the left lower limb since 16 years. On assessment and thorough evaluation, the patient was diagnosed with chronic primary lymphedema of left lower limb with secondary grade 7 skin changes (WHO grading) with multiple fissures over the affected limb (Figure 1). She also had foul-smelling serous discharge from the limb.

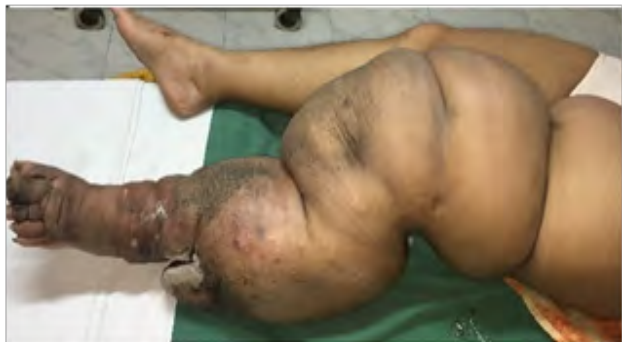

Figure 1: Left lower limb lymphedema.

Videodermatoscopy was done using Aram Huvis® videodermatoscope with 1x, 60x (Figure 2), 200x (Figure 3), 1000x (Figure 4) with Skin XP Pro software system.

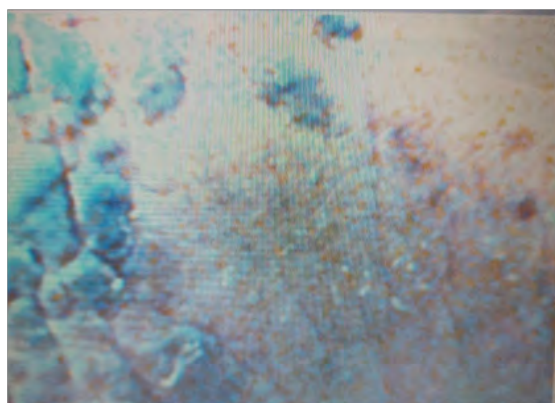

Figure 2: 60x magnification showing scales with pigmented skin.

Result

In our case, we have done serial videodermatoscopy. The changes noted included deep fissures in some areas with scaling of the skin.

Large scabs over various areas. We noticed that our patient had dryness of the skin which was managed. Improvement was noticed by the healing of the fissures over the skin and was recorded using the videodermatoscope.




Figure 3: 200x magnification with fissures and scales and pigmentation.

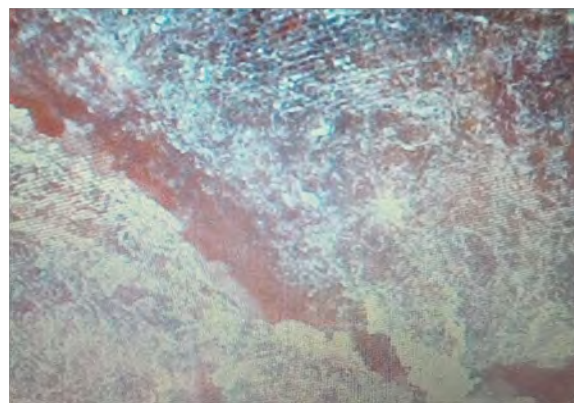

Figure 4: 1000x magnification showing deep fissures with dry scaly skin.

Discussion

Videodermatoscopy is an evolved version of dermatoscopy. It is performed by a video camera equipped with opticfibers and lenses that allow magnifications ranging from 4x to 1000x. The images are visualized on a monitor and stored using a specific software on a personal computer. This helps to identify and compare changes over time [3]. Videodermatoscopy has great potential in differentiating various dermatological conditions and in the differential diagnosis of pigmented skin lesions, including some inflammatory diseases, cutaneous parasitoses like scabies, hair and nail abnormalities, various vascular lesions. In several disorders, it may be useful in differential diagnosis, prognostic evaluation, and in evaluating the response to treatment [3].

In lymphedema, the videodermatoscope not only helps in recording the progress of the skin changes with serial images, it also helps in identifying potential sites of entry of infection by accurately identifying the deep fissures [4], areas of dryness, or fungal infection which

can then be treated appropriately. Also, it is valuable in identifying a possible source of infection which will help in preventing serious infections and the vicious cycle of skin thickening and more fissures leading to repeated infections.

It also helps in identifying and diagnosing the dreaded complication of lymphedema i.e., lymphangiosarcoma [5].

Conclusion

Our experience with videodermatoscope in lymphedema has shown that it can be used in the armamentarium of the investigation modalities to record and follow-up the skin changes during the course of the disease. Further regular evaluation may also lead to a classification system for skin changes may be formulated. However larger studies are required to emphasize the use of videodermatoscopy in all cases of lymphedema during evaluation.

References

1. Micali G, Lacarrubba F (2003) Possible applications of videodermatoscopy beyond pigmented lesions. *International journal of dermatology*. 42: 430-433.
2. Dreyer G, Addiss D, Bettinger J, Dreyer P, Norões J, et al. (2001) Lymphoedema staff manual: treatment and prevention of problems associated with lymphatic filariasis. In *Lymphoedema staff manual: treatment and prevention of problems associated with lymphatic filariasis*, WHO, Geneva, Switzerland.
3. Micali G, Lacarrubba F (2010) *Dermatoscopy in clinical practice: Beyond pigmented lesions*. CRC Press, Florida, USA.
4. Le Fourn E, Duhard E, Tauveron V, Maruani A, Samimi M, et al. (2011) Changes in the nail unit in patients with secondary lymphoedema identified using clinical, dermoscopic and ultrasound examination. *Br J Dermatol* 164: 765-770.
5. Kelati A, Debagh F, Mernissi FZ (2018) Dermoscopy in a lymphangiosarcoma of Stewart–Treves syndrome. *Breast Cancer Management* 7: 12.



- Journal of Anesthesia & Clinical Care
Journal of Addiction & Addictive Disorders
Advances in Microbiology Research
Advances in Industrial Biotechnology
Journal of Agronomy & Agricultural Science
Journal of AIDS Clinical Research & STDs
Journal of Alcoholism, Drug Abuse & Substance Dependence
Journal of Allergy Disorders & Therapy
Journal of Alternative, Complementary & Integrative Medicine
Journal of Alzheimer's & Neurodegenerative Diseases
Journal of Angiology & Vascular Surgery
Journal of Animal Research & Veterinary Science
Archives of Zoological Studies
Archives of Urology
Journal of Atmospheric & Earth-Sciences
Journal of Aquaculture & Fisheries
Journal of Biotech Research & Biochemistry
Journal of Brain & Neuroscience Research
Journal of Cancer Biology & Treatment
Journal of Cardiology: Study & Research
Journal of Cell Biology & Cell Metabolism
Journal of Clinical Dermatology & Therapy
Journal of Clinical Immunology & Immunotherapy
Journal of Clinical Studies & Medical Case Reports
Journal of Community Medicine & Public Health Care
Current Trends: Medical & Biological Engineering
Journal of Cytology & Tissue Biology
Journal of Dentistry: Oral Health & Cosmesis
Journal of Diabetes & Metabolic Disorders
Journal of Dairy Research & Technology
Journal of Emergency Medicine Trauma & Surgical Care
Journal of Environmental Science: Current Research
Journal of Food Science & Nutrition
Journal of Forensic, Legal & Investigative Sciences
Journal of Gastroenterology & Hepatology Research
Journal of Gerontology & Geriatric Medicine
Journal of Genetics & Genomic Sciences
Journal of Hematology, Blood Transfusion & Disorders
Journal of Human Endocrinology
Journal of Hospice & Palliative Medical Care
Journal of Internal Medicine & Primary Healthcare
Journal of Infectious & Non Infectious Diseases
Journal of Light & Laser: Current Trends
Journal of Modern Chemical Sciences
Journal of Medicine: Study & Research
Journal of Nanotechnology: Nanomedicine & Nanobiotechnology
Journal of Neonatology & Clinical Pediatrics
Journal of Nephrology & Renal Therapy
Journal of Non Invasive Vascular Investigation
Journal of Nuclear Medicine, Radiology & Radiation Therapy
Journal of Obesity & Weight Loss
Journal of Orthopedic Research & Physiotherapy
Journal of Otolaryngology, Head & Neck Surgery
Journal of Protein Research & Bioinformatics
Journal of Pathology Clinical & Medical Research
Journal of Pharmacology, Pharmaceutics & Pharmacovigilance
Journal of Physical Medicine, Rehabilitation & Disabilities
Journal of Plant Science: Current Research
Journal of Psychiatry, Depression & Anxiety
Journal of Pulmonary Medicine & Respiratory Research
Journal of Practical & Professional Nursing
Journal of Reproductive Medicine, Gynaecology & Obstetrics
Journal of Stem Cells Research, Development & Therapy
Journal of Surgery: Current Trends & Innovations
Journal of Toxicology: Current Research
Journal of Translational Science and Research
Trends in Anatomy & Physiology
Journal of Vaccines Research & Vaccination
Journal of Virology & Antivirals
Archives of Surgery and Surgical Education
Sports Medicine and Injury Care Journal
International Journal of Case Reports and Therapeutic Studies
Journal of Ecology Research and Conservation Biology

Submit Your Manuscript: <http://www.heraldopenaccess.us/Online-Submission.php>