



## Research Article

### Component Separation or Mesh Repair for Ventral Hernia Repair - The Role of Mesh in Covering all the Abdominal Wall in the Component Repair

Eldo E Frezza<sup>1\*</sup>, Cory Cogdill<sup>2</sup>, Mitchell Wachtell<sup>3</sup> and Edoardo GP Frezza<sup>4</sup>

<sup>1</sup>Eastern New Mexico University, Health Science Center, Roswell NM, USA

<sup>2</sup>Mathematics, Physics and Science Department, Eastern New Mexico University, Roswell NM, USA

<sup>3</sup>Texas Tech University, Lubbock TX, USA

<sup>4</sup>University of Delaware, Newark DE, USA

#### Abstract

Simple repair of the hernia opening, Ventral Hernia Repair (VHR) has been confronted by a more definitive goal of restoration of abdominal muscular strength and wall function accomplished by mobilizing abdominal wall muscles and closing with inlay mesh, Component Separation Repair (CSR). Our observation was based on the notion that shear forces cause herniation and therefore that is an affliction of the entire abdominal wall, not a localized event. We took that information and we compare a series of VHR patients with a series of CSR patients would provision evidence to improve the relative value of the techniques.

**Material:** Retrospective comparison of 30 consecutive CSR patients and 30 consecutive VHR patients was obtained. All abdominal wall hernia defects were at least 10 cm<sup>2</sup> in size. T tests with unequal variances were used to evaluate differences in means of continuous variables and to estimate 95% confidence intervals of differences.

**Results:** Although CSR patients were older, had higher BMI's and higher ASA scores than did VHR patients, the odds of recurrence for CSR patients were less than for VHR patients ( $P < 0.0001$ ). Differences in respects to ileus and wound complications, while they favored CSR patients, might have been due to chance ( $P > 0.05$  for each analysis). In VHR group 11 patients required CSR after 9-24 months, 14 patients have prolonged ileus. In the CSR group two pa-

tients were reoperated for removal of midline skin changes, two for severe seromas requiring wash up of the subcutaneous and fascia area and placement of a wound vacuum on top of the mesh.

**Conclusion:** This study supports the notion that a ventral hernia reflects a defect in the abdominal wall not just the point at which the hernia forms. To avoid a point of rupture, we support highly the CSR technique, since hernia is an abdominal disease not just a hole.

**Keywords:** Abdominal wall physiology; Biological mesh; Component separation; Cross sectional area; Elastic force; Phasix mesh; Polypropylene mesh; Tensile force; Ventral hernia; Ventral hernia repair

#### Introduction

The correction of abdominal wall hernias has presented a surgical challenge for decades. Simple repair of the hernia opening, Ventral Hernia Repair (VHR), has been confronted by a more definitive goal of restoration of abdominal muscular strength and wall function, accomplished by mobilizing abdominal wall muscles and closing with inlay mesh, Component Separation Repair (CSR) [1]. CSR mobilizes fresh muscle medially to reinforce the region of herniation, while preserving fascia associated muscle, and fascia of the rectus muscle, with closure at the line a alba [1]. Both synthetic and non-synthetic mesh has been used for VHR and CSR; non-synthetic mesh, now more popular because of its decreased infection risk, has been derived from human dermis, porcine dermis and bovine small intestinal submucosa [2,3].

The abdominal wall has been exposed to many shear force stress during a life cycle from exercise to pregnancy, from aging to support extra weight in the obesity scenario and wall function [4,5]. We understand that all hernias repair need a mesh, but we hypothesize that by placing the mesh after mobilization of the muscle decrease the tension on the mesh and therefore decrease the recurrences. We retrospectively compare a cohort of VHR patients with one of CSR patients with similar age and BMI with the provision evidence to resolve the relative value of the techniques. Our Hypothesis was that the CSR patient will have fewer recurrences than VHR specifically in the case a mesh will used to cover all the abdominal wall and not just part of it during the repair.

#### Materials and Methods

##### Comparisons of CSR and VHR patient series

Institutional Review Board (IRB) approval was obtained for the retrospective comparison of consecutive CSR patients and VHR patients. All abdominal wall hernia defects were at least 10 cm<sup>2</sup> in size. All the procedures were performed from the same surgeon (EEF), in same hospital settings. Charts and intraoperative notes were collected together with office follow up visits. We evaluated age, gender, hernia size, ASA class as published by the Anesthesia society web page, type of hernia repair and follow up. Patient with less than 12 months follow up were excluded. From the charts review and the operative notes the patients characteristics were collected and summarized into table 1.

\*Corresponding author: Eldo E Frezza, Eastern New Mexico University, Health Science Center, Roswell NM, USA, Tel: +1 956-357-7355; E-mail: eefrezza@msn.com

**Citation:** Frezza EE, Cogdill C, Wachtell M, Frezza EGP (2017) Component Separation or Mesh Repair for Ventral Hernia Repair -The Role of Mesh in Covering all the Abdominal Wall in the Component Repair. J Gastroenterol Hepatology Res 2: 008.

**Received:** July 19, 2017; **Accepted:** September 20, 2017; **Published:** October 06, 2017

	CSR	VHR		
Continuous Variables	Mean (SD)	Mean (SD)	P*	Difference (95% CI)
Age(y)	59 (7)	48 (5)	<0.0001	11 (8, 14)
BMI kg/m <sup>2</sup>	48 (8)	39 (5)	<0.0001	9 (6, 12)
Size Hernia (cm)	18 (5)	12 (2)	<0.0001	6 (4, 8)
OR time (min)	125 (35)	118 (65)	0.6	7 (-20, 34)
Categorical Variables	N (%)	N (%)	P**	Odds Ratio (95% CI)
ASA 1	0 (0%)	0 (0%)		
ASA 2	6 (20%)	15 (50%)		
ASA 3	20 (67%)	12 (40%)		
ASA 4	4 (13%)	3 (10%)		
Total	30 (100%)	30 (100%)	0.048	N/A
Ileus	6 (20%)	14 (47%)		
No Ileus	24 (80%)	16 (53%)		
Total	30 (100%)	30 (100%)	0.0539	0.29 (0.07, 1.02)
Wound Problems	4 (13%)	7 (23%)		
No Wound Problems	26 (87%)	23 (77%)		
Total	30 (100%)	30 (100%)	0.51	0.51 (0.10, 2.32)
Reoperation	0 (0%)	11 (37%)		
No Reoperation	30 (100%)	19 (63%)		
Total	30 (100%)	30 (100%)	0.0003	0.00 (0.00, 0.30)

**Table 1:** CSR and VHR data and statistical analyses.

\*T test with unequal variances

\*\*Two tailed Fisher exact test

Only the patients that match the inclusion criteria were considered. The inclusion criteria were:

#### VHR Group

1. Ventral hernia
2. Incisional hernia
3. Follow up more than 36 months

#### CSR Group

1. Ventral hernia
2. Incisional hernia
3. Recurrent ventral hernia
4. Failure of other procedures
5. Follow up more than 36 months

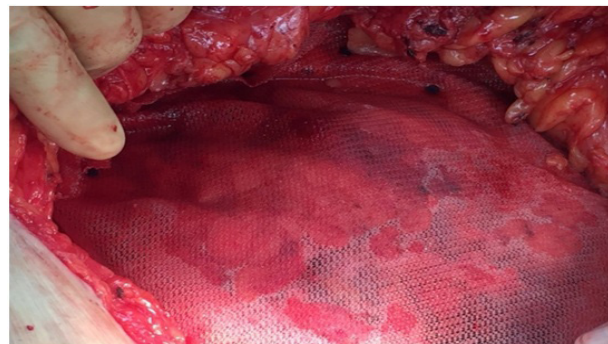
Patient were selected to match age and gender to create 2 cohorts, similar to achieve a good potential comparison. The number 30 was based on the potential to obtain statistical significant analysis.

### Surgical techniques

#### Component Surgical Repair (CSR)

After arrival in the operating room, general endotracheal anes-

thesia was induced. Betadine was applied to the skin. The abdominal wall was opened via the old incision or the region of recurrent herniation, almost always near the old incision cite. A scalpel blade incised the skin. Bovie cautery took down the incision and opened the fascia. Upon entry into the abdominal cavity proper, inspection for intestinal adhesions to the wall or the omentum was undertaken. Metzenbaum scissors and bovie cautery were used for lysis of adhesions, after which intestines and omentum were reinserted into the abdomen. Fascia of the hernia was then inspected, after which subcutaneous fascia was dissected bilaterally from the midline to the anterior axillary line, with hemostasis obtained via bovie and 2-0/3-0 vicryl stitches. After obtaining visualization of the rectus and oblique muscles to the anterior axillary line, the fascia of the oblique muscle and the rectus muscle was opened to permit a relaxing incision and to lengthen the abdominal wall muscle. After bilateral relaxing incisions were made, a running 1-0 vicryl suture closed the primary incision. Large absorbable mesh (Phasix) then was placed over the abdominal wall from the anterior axillary line on one side to the other side up to the sternoxiphoid area and down to the pubic area. Mesh was secured to fascia behind relaxing incisions with 1-0 vicryl, 360 degrees (Figure 1).



**Figure 1:** Phasix mesh in place after CSR.

Mesh was then inspected for tightness and wrinkles; wrinkles, seen in only two patients, were repaired with figure-of-eight stitches to fascia. The abdominal wall was then washed with saline. Two Jackson-Pratt #10 drains were inserted on each side of the flank coming down to the pubis area, secured to skin with 2-0 nylon. Subcutis was reapproximated with 2-0 vicryl. Skin was closed with staples. One dose of first generation cephalosporin was given before surgery; one dose, after surgery.

#### Ventral Hernia Repair (VHR)

After arrival in the operating room, general endotracheal anesthesia was induced. Betadine was applied to the skin. The abdominal wall was opened via the old incision or the region of recurrent herniation, almost always near the old incision cite. A scalpel blade incised the skin. Bovie cautery took down the incision and opened the fascia. Upon entry into the abdominal cavity proper, inspection for intestinal adhesions to the wall or the omentum was undertaken. Metzenbaum scissors and bovie cautery were used for lysis of adhesions, after which intestines and omentum were reinserted into the abdomen. Fascia of the hernia was then inspected, after which subcutaneous fascia was dissected sufficiently about the hernia to permit a relaxing incision to be made, with hemostasis obtained via bovie and 2-0/3-0 vicryl stitches. Ventralite XT mesh was then placed over the opened

fascia, with vicryl 1-0 or PDS 0 used to secure the mesh (Ventralite XT) to the surrounding fascia. Mesh was then inspected for tightness and wrinkles, which were never observed. Two Jackson-Pratt #10 drains were inserted into the flank coming down to the pubis area, secured to skin with 2-0 nylon. Subcutis was reapproximated with 2-0 vicryl. Skin was closed with staples. One dose of first generation cephalosporin was given before surgery; one dose, after surgery.

### Mesh used

We used non-absorbable mesh in the VHR patients and absorbable (biological and none) mesh in the CSR group. We placed a large absorbable mesh to cover the abdominal wall after the CSR operation in all patient and the porcine derived mesh in all but 2, in which we did not have tension and therefore we did not need to fill the gap. In the VHR group the mesh was the ventralite® (CR Bard/Davol, Inc, Warwick, RI, USA), a synthetic mesh, is a propylene polypropylene mesh with one side hydrogel seprafilm was used in 20 out of 30 patients in the VHR group, regular polypropylene mesh was used in the remaining after closing the defect. Phasix® (CR Bard/Davol, Inc, Warwick, RI, USA), a synthetic mesh, a Poly-4-Hydroxybutyrate (P4HP) monofilament, was used in all patients in the CSR group to cover the all abdomen, by including the relaxing incision. In 28 patients porcine derived mesh. Xen Matrix® (CR Bard/Davol, Inc, Warwick, RI, USA), derived from porcine dermis, was also used in the CSR group, when the gap between the fascia was too large that will results in excessive tension. We used porcine mesh in large ventral because can be absorbed and is more resistant to infection.

### Postoperative care

Abdominal binders were used on all patients, who, after being placed on the surgical floor, received incentive spirometry was used on all the patients. Between postoperative days 2 and 3, feeding was begun, with clear liquid diet advanced to full liquid and then to soft diet. Patients were discharged to home after 4-5 days. Jackson Pratt drains were removed in outpatient clinic ten days after the procedure.

Patient follow up was as follow: 2 and 6 weeks. 3-6-9-12 months then every six months.

Our follow up was: 48+9 months in VHR group and 38+6 months in CSR group.

### Statistical methods

T tests with unequal variances were used to evaluate differences in means of continuous variables and to estimate 95% confidence intervals of differences. A Fisher's exact test was used to assess differences in proportions, with binomial odds ratio estimates and 95% confidence intervals being calculated for four-fold tables.

### Results

Table 1 displays the data and statistical analyses for this study. Although CSR patients were older, had higher BMI's and higher ASA scores than did VHR patients, the odds of recurrences for CSR patients were less than for VHR patients ( $P < 0.0001$ ). Differences in respects ileus and wound complications, while they favored CSR patients, might have been due to chance ( $P > 0.05$  for each analysis).

One patient was discharged after twenty-one days; three patients after nine days. Discharge delays stemmed from extensive lysis of adhesions with associated ileus. One patient developed pneumonia

postoperatively requiring a pulmonary consult and a bronchoscopy with lavage. She went home on postoperative day #9 with antibiotics. No surgical complications were found. All the patients got the drainage out within 2 weeks since all the patients followed up 1 week after surgery with us in the office where the Jackson-Pratt was taken off, and in the case of the patient that stayed longer, both the Jackson-Pratt and the staples were taken out in appropriate time which is 1 week after surgery for the Jackson-Pratt and 2 weeks for removal of the staples. In VHR group 11 patients required CSR after 9-24 months, 14 patients has prolonged ileus, 7 had seroma required interventional radiology drainage. In the CSR group 1 patient that had the surgery plus very extensive lysis of adhesions which we waited 4 days when she had some flatus before starting to be fed, and she spent almost 3 weeks in the hospital. In the CSR group two patient were reoperated for removal of midline skin changes, two for severe seromas requiring wash up of the subcutaneous and placement of a wound vacuum.

### Discussion

Abdominal wall defect represents is a surgical challenge, given that in many years we did not achieved a consensus on what was the best operation. It requires appropriate management and decision making for acceptable results [5,6]. CSR and VHR have been employed satisfactorily when mesh has been used, with CSR being recommended when fistula is present, when infection is likely, and after ileostomy or colostomy closure [6-8]. In general CSR has been using for complex cases and given that a non absorbable mesh is rarely indicated given the risk of infection, as in our case when we have to close the gap we always used the porcine derived mesh which is more resistant to infections and do better in case we need to use wound vacuum. This paper shows, in terms of reoperative rates, a marked preference for CSR as a first-choice procedure, a recommendation that concurs with the findings of others [9]. What the physical experiments demonstrated was that differences in reoperative rate might relate to the body habitus and local factors with respect to the abdominal wall strength [4]. Based on this research we thought that one way to improve the strength of the abdominal wall was to reinforced the abdomen by placing an absorbable mesh from the relaxing incision.

The issue remains to decide which operative procedure are the best. Lately the CRS has become more popular given the recurrence of the regular mesh repair and the technical difficulty of the rives stoppa repair procedure which precludes its application to all patients on a routine basis, its low reoperation rate not with standing [10]. A partitional technique involving component separation and fascia-fascia closure has both high risk of short term post-operative complications, as well as a long operative time [11]. Open ventral hernia repair with component separation is appropriate for complex hernias, not simply hernias in patients with infection or other relatively simple problems [12]. Staging of the ventral hernia has been helpful in surgical decision and in post-operative comparison of results [13]. The open intraperitoneal technique is appropriate for complex incisional hernias occurring in obese patients, but is contraindicated when laparoscopic access has been obtained; minimal access was shown to be feasible in patients with a larger mesh of 15 cm [14-16]. A cellular dermal matrix has been also suggested in this cases to resist to infection as well as porcine [3,17]. Open component separation, which allows autologous tissue repair with approximation of a midline fascia in patients with complex hernias, creates large skin flaps that prevent the visualization of epigastric vessels; this problem notwithstanding recurrence rates is similar for open and laparoscopic techniques

[14,15,17]. Although there is a trend towards laparoscopic surgery the laparoscopic repair does not resolve the matter of the ventral hernia's being a problem with the abdominal wall [18-23]. Component graph separation, used to correct large ventral hernias, can yields complications in few patients but this was also an early paper where this surgery was done in complicated cases [24,25]. Posterior repair have been showed similar results, if not better overall [12,26].

As showed by early research a good abdominal reconstruction was improving the physiology of the abdominal wall [4]. In our experience the CSR patient despite presented with more risk factors (higher BMI and higher ASA classification risk) did better than the VHR patient as far as recurrences since the repair was not aimed to close the abdomen gap but to mobilizing and reinforce the whole abdominal wall with a large absorbable mesh, which in our opinion was the major key for the success of our CSR procedures.

These last evidences together with the failing of the above described procedures have been the basic force for surgeons to find alternative procedure like the CRS.

On top of that there are same physic evidence could be garnered from evaluation of elastic band experiments to support or deny the notion that shear forces cause herniation and therefore that is an affliction of the entire abdominal wall, not a localized event. These observations, were emphasized by our tensile experiments, where we showed that a thicker elastic material holds more weight than a thinner one despite similar length ( $P < 0.0001$ ) [27]. This gives us a way to compare different materials based upon the same cross-sectional area. The tensile strength is about 1.5 times the shear strength in material. If then we considered the length of the rubber band we notice that comparing bands with the same thickness the difference in strength is significant different with a confidence level of  $\alpha = 95$ , making the short band the strongest. We are doing more works in this arena to compare tensile strength in elastic materials that would accurately model the muscle tissue strength by calculating the shear forces able to break a hernia repair with mesh. The "snap point" is closed to the suture line as we found often in clinical scenario. It would be helpful to compile clinical data that would identify if failure is between the mesh and the muscle (as a shear force) or if the reoccurrences.

## Conclusion

This study supported the notion that a ventral hernia reflects a defect in the abdominal wall not just the point at which the hernia forms. In our 4 years follow up we reported more recurrences in the VHR group than in the CSR one. The reoperative rates to be greater for conventional ventral hernia repair than for component separation repair, even though the patients who underwent component separation repair were older, had greater body mass indexes, and more severe ASA grades. By sheer force of gravity, we increase the possibility of having a hernia, since the muscle get thinner or the stitches of previous mesh placed has too much tension. To avoid a point of rupture around the mesh and a better long term repair we support highly the CSR technique with a large mesh covering the abdominal wall, since hernia is an abdominal disease not just a hole.

## References

1. Pauli EM, Rosen MJ (2013) Open ventral hernia repair with component separation. *Surg Clin North Am* 93: 1111-1133.

2. Rosen MJ, Krpata DM, Ermlich B, Blatnik JA (2013) A 5 year clinical experience with single staged repairs of infected and contaminated abdominal wall defects utilizing biological mesh. *Ann Surg* 257: 991-996.
3. Pomahac B, Aflaki P (2010) Use of a Non-Cross-Linked Porcine Dermal Scaffold in Abdominal Wall Reconstruction. *Am J Surg* 99: 22-27.
4. Criss CN, Petro CC, Krpata DM, Seafler CM, Lai N, et al. (2014) Functional abdominal wall reconstruction improves core physiology and quality of life. *Surgery* 156: 176-182.
5. Koltz PF, Frey JD, Bell DE, Giroto JA, Christiano JG, et al. (2013) Evolution of abdominal wall reconstruction: development of a unified algorithm with improved outcomes. *Ann Plast Surg* 71: 554-560.
6. Raigani S, De Silva GS, Criss CN, Novitsky YW, Rosen MJ (2014) The impact of developing a comprehensive hernia center on the referral patterns and complexity of hernia care. *Hernia* 18: 625-630.
7. Abdelfatah MM, Rostambeigi N, Podgaetz E, Sarr MG (2015) Long term outcomes ( $> 5$  years follow up) with porcine acellular dermal matrix (permacol) in incisional hernias at risk for infection. *Hernia* 19: 135-140.
8. Lasses Martínez B, Peña Soria MJ, Cabeza Gómez JJ, Jiménez Valladolid D, Flores Gamarra M, et al., (2016) Surgical treatment of large incisional hernias with intraperitoneal composite mesh: a cohort study. *Hernia* 21: 253-260.
9. Sriussadaporn S, Sriussadaporn S, Pak-Art R, Kritayakirana K, Prichayudh S, et al. (2013) Management of difficult abdominal wall problems by components separation methods: a preliminary study in Thailand. *J Med Assoc Thai* 96: 1449-1462.
10. Heartsill L, Richards ML, Arfai N, Lee A, Bingener-Casey J, et al. (2005) Open Rives Stoppa ventral hernia repair made simple and successful but not for everyone. *Hernia* 9: 162-166.
11. Shih PK (2015) Difficult abdominal; wall closure: component separation versus partition technique. *Hernia* 19: 301-305.
12. Pauli EM, Wang J, Petro CC, Juza RM, Novitsky YW, et al., (2015) Posterior component separation with transverses abdominis release successfully addresses recurrent ventral hernias following anterior component separation. *Hernia* 19: 285-291.
13. Petro CC, O'Rourke CP, Posielski NM, Criss CN, Raigani S, et al., (2016) Designing a ventral hernia staging system. *Hernia* 20: 111-117.
14. Bernard C, Polliand C, Mutelica L, Champault G (2007) Repair of giant incisional abdominal wall hernias using open intraperitoneal mesh. *Hernia* 11: 315-320.
15. Ferrari GC, Miranda A, Lemia SD, Sansonna F, Magistro C, et al., (2008) Laparoscopic repair of incisional hernia: outcomes of 100 consecutive cases comprising 25 wall defects larger than 15 cm. *Surg Endosc* 22: 1173-1179.
16. Mommers EH, Wegdam JA, Nienhuijs SW, de Vries Reilingh TS (2016) How to perform the endoscopically assisted components separation technique (ECST) for large ventral hernia repair. *Hernia* 20: 441-447.
17. Roth JS, Brathwaite C, Hacker K, Fisher K, King J (2015) Complex ventral hernia repair with a human acellular dermal matrix. *Hernia* 19: 247-252.
18. Albright E, Diaz D, Davenport D, Roth JS (2011) The component separation technique for hernia repair: a comparison of open and endoscopic techniques. *Am Surg* 77: 839-843.
19. Gonzalez R, Rehnke RD, Ramaswamy A, Smith CD, Clarke JM, et al. (2005) Components separation technique and laparoscopic approach: a review of two evolving strategies for ventral hernia repair. *Am Surg* 71: 598-605.

20. Bachman SL, Ramaswamy A, Ramshaw BJ (2009) Early results of mid-line hernia repair using minimal invasive component separation technique. *Am Surg* 75: 572-578.
21. Wright BE, Niskanen BD, Peterson DJ, Ney AL, Odland MD, et al. (2002) Laparoscopic ventral hernia repair: are there comparative advantages over traditional methods of repair? *Am Surg* 68: 291-296.
22. Rosen MJ (2009) Polyester based mesh for ventral hernia repair: is it safe? *Am J Surg* 197: 353-359.
23. Singh DP, Zahiri HR, Gastman B, Holton LH, Stromberg JA, et al. (2014) A modified approach to component separation using biological graft as a load sharing onlay reinforcement for the repair of complex ventral hernia. *Surg Innov* 21: 137-146.
24. Rosen MJ, Bauer JJ, Harmaty M, Carbonell AM, Cobb WS, et al., (2017) Multicentric prospective longitudinal study of the recurrence, surgical site infection and quality of life after contaminated ventral hernia repair using biosynthetic absorbable mesh: the COBRA study. *Ann Surg* 265: 205-211.
25. Fischer JP, Wink JD, Nelson JA, Kovach SJ 3<sup>rd</sup> (2014) Among 1,706 cases of abdominal wall reconstruction, what factors influence the occurrence of major operative complications? *Surgery* 155: 311-319.
26. Jones CM, Winder JS, Potochny JD, Pauli EM (2016) Posterior component separation with transverses abdominis release: technique, utility and outcomes in complex abdominal wall reconstruction. *Plast Reconstr Surg* 137: 636-646.
27. Frezza EE, Cogdill C, Wacthell M, Frezza EGP (2017) A Physic Tensile Forces Experiment to Possible Explain the Reason of Failing Ventral Hernia Repair. *J Gastroenterol Hepatology Res* 2: 007.