

Case Report

Pleural Effusion as a Complication of Umbilical Venous Catheter

Sara Machado Rocha^{1*}, Catarina M Lacerda², Margarida Rosal³, Carla David³ and Teresa Tomé³

¹Department of Pediatrics, Hospital de Santarém, Santarém, Portugal

²Department of Pediatrics, Centro Hospitalar Barreiro-Montijo, Santarém, Portugal

³Department of Pediatrics, Centro Hospitalar de Lisboa Central, Santarém, Portugal

Abstract

Umbilical Venous Catheterization (UVC) is a common practice in neonatal units, though not without risks. Complications may occur in over 20% of patients; however pleural effusion is extremely rare. We report a case of an extreme preterm male neonate weighing 810 g, who developed pleural effusion due to malpositioned UVC. Pleural fluid was biochemically similar to parenteral nutrition solution. This alongside with the absence of recurrence of pleural effusion after UVC removal, support the causality between the UVC and pleural effusion. This case emphasizes the need to confirm the correct positioning of UVC. When in doubtful position, it should be withdrawn as early as possible, ensuring an alternative central access. If the clinical situation does not allow it, it is important to consider the osmolarity of the perfused solution, due to the risk of endothelial damage.

Keywords: Neonate; Parenteral nutrition; Pleural effusion; Umbilical venous catheter

*Corresponding author: Sara Machado Rocha, Department of Pediatrics, Hospital de Santarém, Santarém, Portugal, Tel: +351 918178259; E-mail: sararocha.smr@gmail.com

Citation: Rocha SM, Lacerda CM, Rosal M, David C, Tomé T (2018) Pleural Effusion as a Complication of Umbilical Venous Catheter. J Neonatol Clin Pediatr 5: 026.

Received: November 15, 2018; **Accepted:** December 06, 2018; **Published:** December 20, 2018

Copyright: © 2018 Rocha SM, et al. This is an open-access article distributed under the terms of the Creative Commons Attribution License, which permits unrestricted use, distribution, and reproduction in any medium, provided the original author and source are credited.

Introduction

Umbilical Venous Catheterization (UVC), first described in 1947 by Diamond [1], is a common practice in most neonatal units. It provides a quick and easy access to the systemic circulation, allowing a wide variety of purposes and preventing multiple painful venipunctures. However, this procedure is associated with significant complications [2,3]. Mechanical complications may occur in over 20% of patients, especially if malpositioned [4]. Pleural effusion is rarely reported as a complication of UVC [5].

Clinical Case Report

We report a case of an extreme low birth weight preterm male neonate (810 g, 25 weeks of gestation), delivered by spontaneous vaginal delivery due to cervical incompetence. The APGAR score at first, fifth and tenth minute was 3, 5 and 7, respectively. He was intubated and ventilated at delivery room and initial physical assessment was unremarkable. Upon admission to the Neonatal Intensive Care Unit (NICU), the neonate was accidentally extubated and reintubated, then starting progressive worsening respiratory distress. Right pneumothorax was diagnosed and chest tube placed. Its correct position was confirmed by chest radiograph. The newborn was placed on high frequency oscillatory ventilation and chest drainage active suction, according to the NICU protocol. The umbilical catheters were introduced and the location of catheters tip was verified by anteroposterior chest radiograph. Umbilical Arterial Catheter (UAC) was placed at a low position and was removed after a few hours, due to vasospasm of the left lower limb. UVC tip was malpositioned at the left upper abdominal quadrant and therefore was withdrawn 1.5 cm. Parenteral nutrition was then initiated, on the first hour of life. Ampicillin and gentamycin were started as empirical treatment. During the first day, blood gases were appropriate (pH 7.35, pCO₂ 35.5 mmHg) and the minimum blood glucose level was 85 mg/dL. At 24 h of life, the neonate became hypotensive and oligoanuric refractory to therapy (saline bolus, inotropic drugs and hydrocortisone) in association with worsening respiratory function, persistent hypoxemia, metabolic acidosis and blood glucose level of 47 mg/dL.

The chest radiograph showed recurrence of the right pneumothorax, due to chest tube malposition (Figure 1). The chest tube was replaced, with an initial drainage of air and serohematic fluid that turned into milky/yellowish (Figure 2), in a total of 164 ml. Cytochemical examination of pleural fluid revealed a predominance of polymorphonuclear cells and a high glucose concentration (1173 mg/dL) that is compatible with parenteral nutrition solution. Peripherally inserted central catheter was placed and UVC removed. After catheter removal, mean arterial pressure, urine output and blood glucose normalized and there was no recurrence of pleural effusion. Chest tube was removed on the fourth day and post-procedure chest radiograph showed clear parenchymal lung fields. Blood culture was sterile, therefore antibiotics were stopped at day 5. The infant remained intubated for 40 days and received parenteral nutrition for 42 days. He was discharged without oxygen at 77th day of life. Brain ultrasound at discharge was normal.

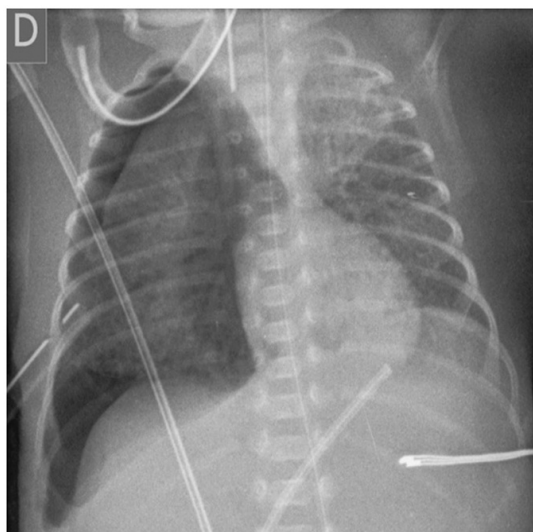


Figure 1: Recurrence of right pneumothorax due to chest tube malposition; UVC tip malpositioned at the left upper abdominal quadrant.

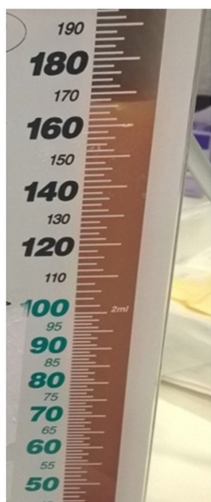


Figure 2: Milky yellowish pleural liquid, corresponding to parenteral nutrition solution.

Discussion

The high glucose concentration in the pleural fluid as well as the absence of recurrence of pleural effusion after catheter removal, support a causal relationship between the UVC and the pleural effusion. A possible mechanism could have been endothelial damage of a small vessel due to hyperosmolarity of parenteral nutrition solution (around 900 mOsm/L), as previously suggested by Traen et al., [5]. The fluid have leaked into the abdominal cavity and crossed the diaphragm openings to the thoracic cavity due to active suction of chest drainage. This explanation supports the late presentation of symptoms.

Correct positioning of the UVC is critical in order to prevent life-threatening complications [2]. The optimal position of the UVC

tip is considered to be just above the diaphragm in the thoracic inferior vena cava or at the cavoatrial junction. The current standard technique used worldwide to localize the catheter tip is Anteroposterior (AP) chest radiography, since it was introduced by Peck and Lowman in 1967 [6]. However, cases have been reported suggesting that complications could occur even when AP chest radiographs revealed a proper position of catheter's tip [7,8]. Lateral views increase the accuracy of chest radiograph in predicting the location of UVC tip, but it results on greater exposure of neonate to radiation [9]. Recently, studies have demonstrated that echocardiography is superior to AP chest radiographs for UVC tip localization [2,10].

We should not forget to check the catheter's tip location after any repositioning, and re-evaluate it regularly is mandatory. When malpositioned or in doubtful position, catheters should be withdrawn as early as possible, ensuring an alternative access. If the clinical situation does not allow it, it is important to consider the osmolarity of the perfused solutions, due to the risk of endothelial damage.

Financial Disclosure

The authors have no financial relationships relevant to this article to disclose.

Conflict of Interest

The authors have no conflicts of interest to disclose.

Contributor's Statement Page

Sara Machado Rocha: Conceived, designed, drafted and revised the manuscript.

Catarina M Lacerda: Reviewed and revised the manuscript.

Margarida Rosal, Carla David and Teresa Tomé: Served as scientific advisors and critically reviewed the manuscript.

All authors approved the final manuscript as submitted and agree to be accountable for all aspects of the work.

References

1. Diamond LK (1947) Erythroblastosis foetalis or haemolytic disease of the newborn. *Proc R Soc Med* 40: 546-550.
2. Pulickal AS, Charlagorla PK, Tume SC, Chhabra M, Narula P, et al. (2013) Superiority of targeted neonatal echocardiography for umbilical venous catheter tip localization: Accuracy of a clinician performance model. *J Perinatol* 33: 950-953.
3. Hoellering AB, Koorts PJ, Cartwright DW, Davies MW (2014) Determination of umbilical venous catheter tip position with radiograph. *Pediatr Crit Care Med* 15: 56-61.
4. Lloreda-García JM, Lorente-Nicolás A, Bermejo-Costa F, Fernández-Fruetoso JR (2016) Complicaciones mecánicas asociadas a la localización de la punta de catéteres centrales en una unidad neonatal. *Anales de Pediatría* 85: 77-85.
5. Traen M, Schepens E, Laroche S, van Overmeire B (2005) Cardiac tamponade and pericardial effusion due to venous umbilical catheterization. *Acta Paediatr* 94: 626-628.
6. Peck DR, Lowman RM (1967) Roentgen aspects of umbilical vascular catheterization in the newborn. The problem of catheter placement. *Radiology* 89: 874-877

7. Unal S, Arifoglu I, Celik IH, Yilmaz O, Bas AY, et al. (2017) Pleural and pericardiac effusion as a complication of properly placed umbilical venous catheter. *J Neonatal Surg* 6: 34.
8. Pabalan M, Wynn RJ, Reynolds AM, Ryan RM, Youssfi M, et al. (2007) Pleural effusion with parenteral nutrition solution: An unusual complication of an “appropriately” placed umbilical venous catheter. *Am J Perinatol* 24: 581-586.
9. Guimarães AF, Souza AA, Bouzada MC, Meira ZM (2017) Accuracy of chest radiography for positioning of the umbilical venous catheter. *J Pediatr (Rio J)* 93: 172-178.
10. Fleming SE, Kim JH (2011) Ultrasound-guided umbilical catheter insertion in neonates. *J Perinatol* 31: 344-349.



Journal of Anesthesia & Clinical Care
Journal of Addiction & Addictive Disorders
Advances in Microbiology Research
Advances in Industrial Biotechnology
Journal of Agronomy & Agricultural Science
Journal of AIDS Clinical Research & STDs
Journal of Alcoholism, Drug Abuse & Substance Dependence
Journal of Allergy Disorders & Therapy
Journal of Alternative, Complementary & Integrative Medicine
Journal of Alzheimer's & Neurodegenerative Diseases
Journal of Angiology & Vascular Surgery
Journal of Animal Research & Veterinary Science
Archives of Zoological Studies
Archives of Urology
Journal of Atmospheric & Earth-Sciences
Journal of Aquaculture & Fisheries
Journal of Biotech Research & Biochemistry
Journal of Brain & Neuroscience Research
Journal of Cancer Biology & Treatment
Journal of Cardiology: Study & Research
Journal of Cell Biology & Cell Metabolism
Journal of Clinical Dermatology & Therapy
Journal of Clinical Immunology & Immunotherapy
Journal of Clinical Studies & Medical Case Reports
Journal of Community Medicine & Public Health Care
Current Trends: Medical & Biological Engineering
Journal of Cytology & Tissue Biology
Journal of Dentistry: Oral Health & Cosmesis
Journal of Diabetes & Metabolic Disorders
Journal of Dairy Research & Technology
Journal of Emergency Medicine Trauma & Surgical Care
Journal of Environmental Science: Current Research
Journal of Food Science & Nutrition
Journal of Forensic, Legal & Investigative Sciences
Journal of Gastroenterology & Hepatology Research
Journal of Gerontology & Geriatric Medicine
Journal of Genetics & Genomic Sciences
Journal of Hematology, Blood Transfusion & Disorders
Journal of Human Endocrinology
Journal of Hospice & Palliative Medical Care
Journal of Internal Medicine & Primary Healthcare
Journal of Infectious & Non Infectious Diseases
Journal of Light & Laser: Current Trends
Journal of Modern Chemical Sciences
Journal of Medicine: Study & Research
Journal of Nanotechnology: Nanomedicine & Nanobiotechnology
Journal of Neonatology & Clinical Pediatrics
Journal of Nephrology & Renal Therapy
Journal of Non Invasive Vascular Investigation
Journal of Nuclear Medicine, Radiology & Radiation Therapy
Journal of Obesity & Weight Loss
Journal of Orthopedic Research & Physiotherapy
Journal of Otolaryngology, Head & Neck Surgery
Journal of Protein Research & Bioinformatics
Journal of Pathology Clinical & Medical Research
Journal of Pharmacology, Pharmaceutics & Pharmacovigilance
Journal of Physical Medicine, Rehabilitation & Disabilities
Journal of Plant Science: Current Research
Journal of Psychiatry, Depression & Anxiety
Journal of Pulmonary Medicine & Respiratory Research
Journal of Practical & Professional Nursing
Journal of Reproductive Medicine, Gynaecology & Obstetrics
Journal of Stem Cells Research, Development & Therapy
Journal of Surgery: Current Trends & Innovations
Journal of Toxicology: Current Research
Journal of Translational Science and Research
Trends in Anatomy & Physiology
Journal of Vaccines Research & Vaccination
Journal of Virology & Antivirals
Archives of Surgery and Surgical Education
Sports Medicine and Injury Care Journal
International Journal of Case Reports and Therapeutic Studies

Submit Your Manuscript: <http://www.heraldopenaccess.us/Online-Submission.php>