Kaya FS, et al., J Ophthalmic Clin Res 2022, 9: 093
DOI: 10.24966/OCR-8887/100093

HSOA Journal of Ophthalmology & Clinical Research

Case Report

A Case of Ocular Ischaemic Syndrome Associated with Choroidal Folds

Fatma Selin Kaya[1]*, Esra Kasapoğlu[2], Umut Onur [2], Öznur İşcan[2], Özgür Örüm[2] and Fadime Ulviye Yiğit[3]

[1]*Başakşehir Çam ve Sakura City Hospital, Ophthalmology Department, Başakşehir, Istanbul, Turkey*

[2]*İstanbul Bakırköy Dr. Sadi Konuk Research and Education Hospital, Ophthalmology Department, Bakırköy, İstanbul, Turkey*

[3]*Avcılar Hospital, Ophthalmology Department, İstanbul, Turkey*

Abstract

A 58 year-old male patient presented with fluctuating vision in right eye. Dilated fundus examination on presentation showed wavy choroidal folds and cotton wool spots in the posterior pole of right eye. Fundus fluorescein angiogram demonstrated prolonged arm-to-retina circulation time and a patchy choroidal filling pattern in the same eye. The carotid evaluation revealed complete stenosis of the right internal carotid artery. We report a case showing choroidal folds can be linked with Ocular Ischaemic Syndrome (OIS) and propose a possible pathogenic mechanism for development of choroidal folds in OIS.

Introduction

Ocular involvement can be observed in carotid disease, and ocular symptoms may be the first sign of carotid artery stenosis [1]. Ocular Ischaemic Syndrome (OIS) is a rare condition, which is caused by ocular hypoperfusion associated with stenosis of the Internal Carotid Artery (ICA) or the common carotid artery [2].

The most common anterior characteristics include iris neovascularization, iridocyclitis, asymmetric cataract, iris atrophy. The main findings of posterior segment are perifoveal telangiectasias, dilated retinal veins, mid-peripheral retinal hemorrhages, microaneurysms, neovascularization at the optic disk and in the retina, a cherry-red spot, cotton-wool spots, vitreous hemorrhage [3].

***Corresponding author:** Fatma Selin Kaya, Başakşehir Çam ve Sakura City Hospital Ophthalmology Department, Başakşehir, 34480, Istanbul, Turkey, Tel: +90 2129096000; E-mail: fatselink@gmail.com

Citation: Kaya FS, Kasapoğlu E, Onur U, İşcan Ö, Örüm Ö (2022) A Case of Ocular Ischaemic Syndrome Associated with Choroidal Folds. J Ophthalmic Clin Res 9: 093.

Received: February 26, 2022; **Accepted:** March 15, 2022; **Published:** March 22, 2022

Copyright: © 2022 Kaya FS, et al. This is an open-access article distributed under the terms of the Creative Commons Attribution License, which permits unrestricted use, distribution, and reproduction in any medium, provided the original author and source are credited.

Although choroidal folds can be seen in association with various conditions [4], OIS is rarely associated with choroidal folds. Therefore, we report a case of OIS with a rare finding of choroidal folds and discuss possible pathogenic mechanisms for development of choroidal folds in OIS.

Case Report

A 58-year-old man presented at our hospital with fluctuating vision in the right eye. Best Corrected Visual Acuity (BCVA) was 0.8 OD and 1.0 OS. The intraocular pressure (IOP) was 16mmHg in the right eye and 22 mmHg in the left eye. In addition, no iris rubeosis, inflammation or relative afferent pupillary defect was observed in either eye. Fundus examination of the right eye demonstrated severe retinal vascular abnormalities with cotton wool spots, choriodal folds and optic disc pallor (Figure 1). At presentation, the optic disk of the right eye had mild edema which was evident on Fluorescein Angiography (FFA) as optic disk staining (Figure 2). FFA showed multiple sites of non-perfusion area and delayed arteriolar filling, suggestive of ocular ischaemie (Figure 3). Erythrocyte Sedimentation Rate (ESR), and C-Reactive Protein (CRP) were within normal limits. The laboratory blood test findings showed that the Lactate Dehydrogenase was 275U/L and the total cholesterol level was 290 mg/dl, suggesting that they were elevated. Orbital magnetic resonance imaging excluded orbital mass. In the present case, retinal cotton wool exudates and prolonged arterial filling in the posterior pole suggested a decrease in ocular blood flow. He immediately started conservative treatment with anti-platelet drugs. In order to evaluate the carotid artery stenosis, a carotid ultrasound was performed, and it showed subtotal occlusion of the right ICA. Subsequently, we performed Magnetic resonance (MR) angiography and MR angiography revealed complete total occlusion of the right ICA and 50% stenosis of the left ICA. We referred the patient to the department of vascular surgery, where it was determined that ICA stenting was necessary for the stenosis.

Figure 1: Fundus photographs of the right and left eye. Fundus photograph of the right eye showed soft exudates and choroidal folds.

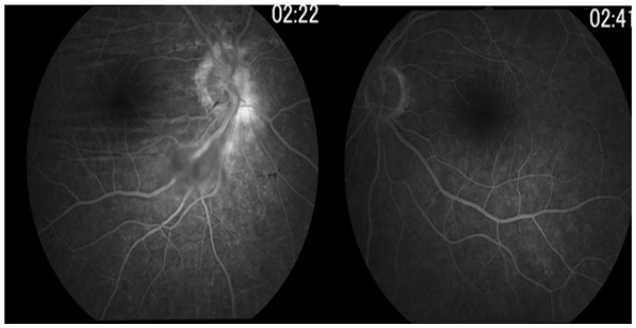

Figure 2: Fundus fluorescein angiography of the right and left eye: hyperfluorescence at the disc margin of the right optic nerve and choroidal folds in the right eye are seen.

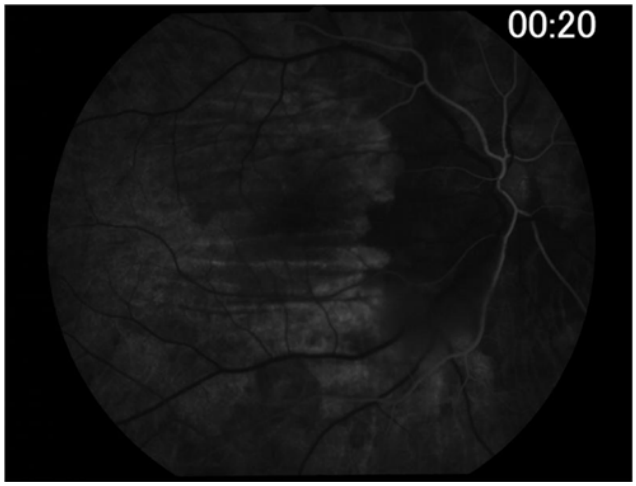

Figure 3: Fundus fluorescein angiography image taken at 20 s (arterial phase) demonstrated prolonged arm-to-retina circulation time and a patchy choroidal filling pattern.

Discussion

Ocular ischemic syndrome is a serious condition that generally causes visual loss and ocular angina. The current case had right OIS due to complete occlusion of the right ICA. The features of OIS in this patient include ocular angina, cotton wool spots and choroidal folds.

Our patient had ocular pain at presentation in the absence of neovascular glaucoma which might suggest ischemia was the likely cause. Normal ESR, CRP and absent suggestive history/clinical features excluded giant cell arteritis in present patient.

Choroidal folds are undulations located in the retinal pigment epithelium, Bruch's membrane, and inner choroid. They are generally associated with orbital disease, choroidal tumors, ocular hypotony, scleritis, ocular inflammation and papilledema [4]. Among the mechanisms which are responsible for choroidal fold formation seen with OİS, a few potential mechanisms can be considered. Ocular hypony might be one of the mechanisms associated with choroidal fold. However, normal intraocular pressure value excluded ocular hypotony in our patient. The intraocular pressure is usually less than 6 mm of Hg in choroidal folds related to hypotony [5]. The second mechanism associated with the choroidal folds in the present case would be the, acute congestion of ocular tissues as a result of decreased blood flow. Choroidal fold formation caused by congestion of the choroid is described previously. In cases with scleritis, acute Vogt-Koyanagi-Harada disease, and papilledema, increased choroidal thickness may be related to choroidal folds [6,7]. Any stenoses of the ICA affect both retinal and choroidal blood flows. Carotid studies revealed complete stenosis of the right internal carotid artery and 50% stenosis of the left internal carotid artery in the present case. Therefore we suggest that sudden occlusion of ICA may result in congestion of the choroid leading to choroidal folds. Factors that cause the normal expansion of Bruch's membrane to shorten are considered to contribute to the development of choroidal folds. Congestion of choroid compressing the Bruch's membrane, followed capillary leakage to the intersistial space results from the total occlusion of ICA (Figure 4). Congestion of the choroid and adhesions to Bruch's membrane are probably prerequisites for folds to form in current case.

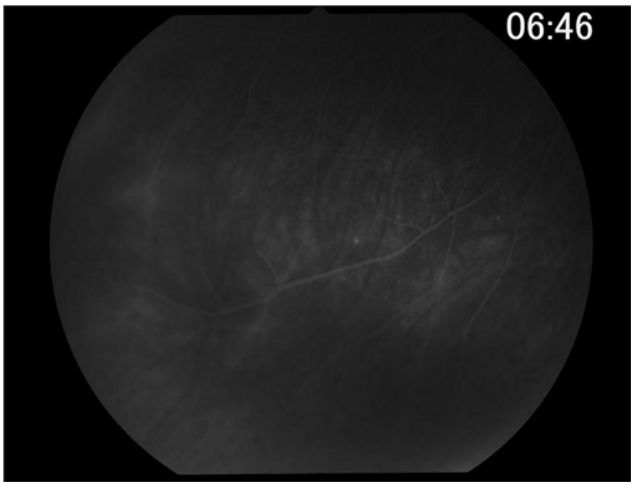

Figure 4: Late phase fundus fluorescein angiography showed peripheral vascular leakage in the right eye.

We reported a patient with total internal carotid artery obstruction who presented with choroidal folds and soft exudates. Congestion of the choroid due to sudden decrease of ocular blood flow and adhesions to Bruch's membrane are considered to contribute to the development of choroidal folds in this case. As clinical diagnosis might be challenging, physicians should be aware of the rare ocular manifestations of this potentially fatal condition.

Funding

The authors declare that they have not received grant support or research funding and they do not have any proprietary interests in the materials described in the article.

Declarations of Interest

None

References

1. Dugan JD Jr, Green WR (1991) Ophthalmologic manifestations of carotid occlusive disease. Eye (Lond) 5: 226-238.

2. Mendrinos E, Machinis TG, Pournaras CJ (2010) Ocular ischemic syndrome. Surv Ophthalmol 55: 2-34.

3. Brown GC, Magargal LE (1988) The ocular ischemic syndrome: clinical, fluorescein angiographic and carotid angiographic features. Int Opthalmol 11: 239-251.

4. Agrawal M, Tripathy K (2022) Choroidal Folds. In: StatPearls Treasure Island (FL): StatPearls Publishing.

5. Bullock JD, Egbert PR (1974) Experimental choroidal folds. Am J Ophthalmol 78: 618-623.

6. Benson WE (1988) Posterior scleritis. Surv Ophthalmol 32: 297-316.

7. Zhao C, Zhang M, Wen X, Dong F, Han B, et al. (2009) Choroidal folds in acute Vogt-Koyanagi-Harada disease. Ocul Immunol Inflamm 17: 282-288.

HERALD

Advances In Industrial Biotechnology | ISSN: 2639-5665

Advances In Microbiology Research | ISSN: 2689-694X

Archives Of Surgery And Surgical Education | ISSN: 2689-3126

Archives Of Urology

Archives Of Zoological Studies | ISSN: 2640-7779

Current Trends Medical And Biological Engineering

International Journal Of Case Reports And Therapeutic Studies | ISSN: 2689-310X

Journal Of Addiction & Addictive Disorders | ISSN: 2578-7276

Journal Of Agronomy & Agricultural Science | ISSN: 2689-8292

Journal Of AIDS Clinical Research & STDs | ISSN: 2572-7370

Journal Of Alcoholism Drug Abuse & Substance Dependence | ISSN: 2572-9594

Journal Of Allergy Disorders & Therapy | ISSN: 2470-749X

Journal Of Alternative Complementary & Integrative Medicine | ISSN: 2470-7562

Journal Of Alzheimers & Neurodegenerative Diseases | ISSN: 2572-9608

Journal Of Anesthesia & Clinical Care | ISSN: 2378-8879

Journal Of Angiology & Vascular Surgery | ISSN: 2572-7397

Journal Of Animal Research & Veterinary Science | ISSN: 2639-3751

Journal Of Aquaculture & Fisheries | ISSN: 2576-5523

Journal Of Atmospheric & Earth Sciences | ISSN: 2689-8780

Journal Of Biotech Research & Biochemistry

Journal Of Brain & Neuroscience Research

Journal Of Cancer Biology & Treatment | ISSN: 2470-7546

Journal Of Cardiology Study & Research | ISSN: 2640-768X

Journal Of Cell Biology & Cell Metabolism | ISSN: 2381-1943

Journal Of Clinical Dermatology & Therapy | ISSN: 2378-8771

Journal Of Clinical Immunology & Immunotherapy | ISSN: 2378-8844

Journal Of Clinical Studies & Medical Case Reports | ISSN: 2378-8801

Journal Of Community Medicine & Public Health Care | ISSN: 2381-1978

Journal Of Cytology & Tissue Biology | ISSN: 2378-9107

Journal Of Dairy Research & Technology | ISSN: 2688-9315

Journal Of Dentistry Oral Health & Cosmesis | ISSN: 2473-6783

Journal Of Diabetes & Metabolic Disorders | ISSN: 2381-201X

Journal Of Emergency Medicine Trauma & Surgical Care | ISSN: 2378-8798

Journal Of Environmental Science Current Research | ISSN: 2643-5020

Journal Of Food Science & Nutrition | ISSN: 2470-1076

Journal Of Forensic Legal & Investigative Sciences | ISSN: 2473-733X

Journal Of Gastroenterology & Hepatology Research | ISSN: 2574-2566

Journal Of Genetics & Genomic Sciences | ISSN: 2574-2485

Journal Of Gerontology & Geriatric Medicine | ISSN: 2381-8662

Journal Of Hematology Blood Transfusion & Disorders | ISSN: 2572-2999

Journal Of Hospice & Palliative Medical Care

Journal Of Human Endocrinology | ISSN: 2572-9640

Journal Of Infectious & Non Infectious Diseases | ISSN: 2381-8654

Journal Of Internal Medicine & Primary Healthcare | ISSN: 2574-2493

Journal Of Light & Laser Current Trends

Journal Of Medicine Study & Research | ISSN: 2639-5657

Journal Of Modern Chemical Sciences

Journal Of Nanotechnology Nanomedicine & Nanobiotechnology | ISSN: 2381-2044

Journal Of Neonatology & Clinical Pediatrics | ISSN: 2378-878X

Journal Of Nephrology & Renal Therapy | ISSN: 2473-7313

Journal Of Non Invasive Vascular Investigation | ISSN: 2572-7400

Journal Of Nuclear Medicine Radiology & Radiation Therapy | ISSN: 2572-7419

Journal Of Obesity & Weight Loss | ISSN: 2473-7372

Journal Of Ophthalmology & Clinical Research | ISSN: 2378-8887

Journal Of Orthopedic Research & Physiotherapy | ISSN: 2381-2052

Journal Of Otolaryngology Head & Neck Surgery | ISSN: 2573-010X

Journal Of Pathology Clinical & Medical Research

Journal Of Pharmacology Pharmaceutics & Pharmacovigilance | ISSN: 2639-5649

Journal Of Physical Medicine Rehabilitation & Disabilities | ISSN: 2381-8670

Journal Of Plant Science Current Research | ISSN: 2639-3743

Journal Of Practical & Professional Nursing | ISSN: 2639-5681

Journal Of Protein Research & Bioinformatics

Journal Of Psychiatry Depression & Anxiety | ISSN: 2573-0150

Journal Of Pulmonary Medicine & Respiratory Research | ISSN: 2573-0177

Journal Of Reproductive Medicine Gynaecology & Obstetrics | ISSN: 2574-2574

Journal Of Stem Cells Research Development & Therapy | ISSN: 2381-2060

Journal Of Surgery Current Trends & Innovations | ISSN: 2578-7284

Journal Of Toxicology Current Research | ISSN: 2639-3735

Journal Of Translational Science And Research

Journal Of Vaccines Research & Vaccination | ISSN: 2573-0193

Journal Of Virology & Antivirals

Sports Medicine And Injury Care Journal | ISSN: 2689-8829

Trends In Anatomy & Physiology | ISSN: 2640-7752

Submit Your Manuscript: https://www.heraldopenaccess.us/submit-manuscript

Herald Scholarly Open Access, 2561 Cornelia Rd, #205, Herndon, VA 20171, USA.
Tel: +1 202-499-9679; E-mail: info@heraldsopenaccess.us
http://www.heraldopenaccess.us/