

## Correspondence Article

### Patent Blue Mixed with Sodium Hyaluronate for Capsulorhexis

Fernando Polit\* and Andres Polit

Hospital Clínica Kennedy, Guayaquil, Ecuador

Clinica Barraquer, Bogotá, Colombia

#### Introduction

In 1999, Melles recommended the use of trypan blue dye to stain the anterior lens capsule for visualizing capsulorhexis in surgery of mature cataracts [1]. However, during the procedure the dye is in contact not only with the anterior capsule but with other anterior segment tissues, in particular the corneal endothelium. Although the complications related to the use of trypan blue have been scarce [2-5], some authors have modified the original technique to limit the dye contact to the anterior capsule [6-8]. Kayikcioglu and coauthors proposed to mix trypan blue 0.4% with sodium hyaluronate 1% in a 1:1 ratio to be injected onto the anterior lens capsule. Thereafter, the mix is washed out and the anterior chamber refilled with a viscoelastic agent to perform the capsulorhexis [9]. We describe a simplification of Kayikcioglu technique.

#### Surgical Technique

A 1 ml insulin syringe is filled with 4 units of Patent blue 0.24%, which is taken directly from the sterile vial. Then, the needle is removed, the plunger is pulled back and through the small opening of the needle adapter 12 units of cohesive sodium hyaluronate 1% are introduced reaching a 1:3 ratio. Dye and cohesive are mixed by pulling forward and back the plunger of the syringe several times. After the anterior chamber paracentesis, a Simcoe cannula is introduced to inject air and the mix simultaneously. The colored viscoelastic material is spread on the anterior lens capsule, while the continuous injection of air facilitates to maintain the anterior chamber depth. Then, a dispersive viscoelastic agent is injected to help to evacuate air and the mix (Figure 1). Finally, more cohesive viscoelastic material is injected in the anterior chamber to protect the corneal endothelium and the capsulorhexis is performed (Figure 2).

\*Corresponding author: Fernando Polit, Hospital Clínica Kennedy, Guayaquil, Ecuador, South America, Tel: +593 042838636; E-mail: fpolith@hotmail.com

Citation: Polit F, Polit A (2016) Patent Blue Mixed with Sodium Hyaluronate for Capsulorhexis. J Ophthalmic Clin Res 3: 021.

Received: June 19, 2016; Accepted: July 09, 2016; Published: July 25, 2016

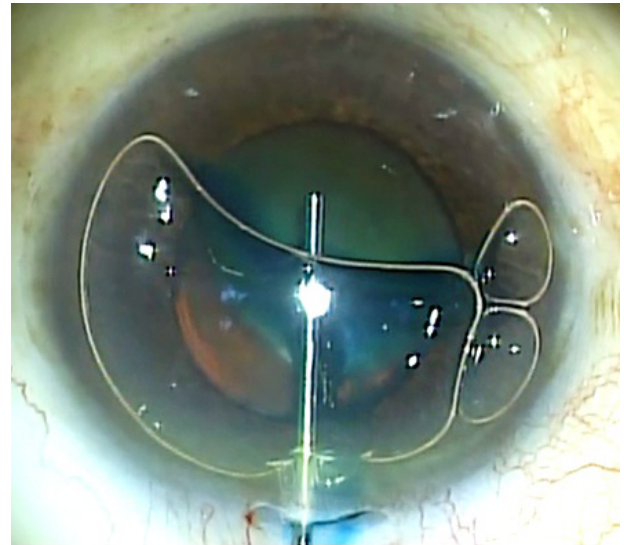


Figure 1: The dispersive viscoelastic helps to evacuate air and the mix.

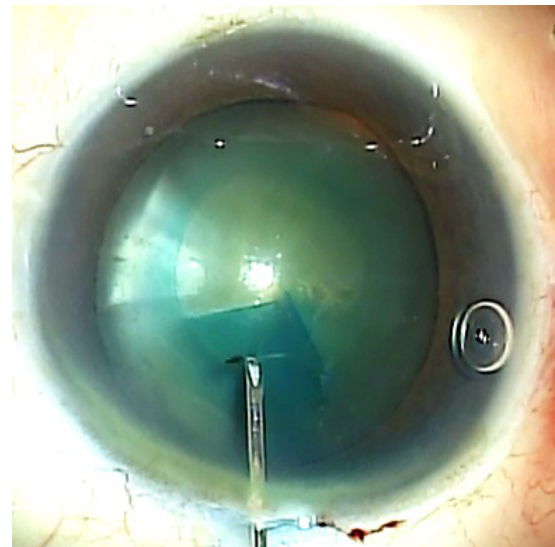


Figure 2: The capsulorhexis is easily performed.

#### Discussion

Patent blue mixed with sodium hyaluronate helps to increase the visibility of the anterior lens capsule during capsulorhexis. Previously, a similar procedure has been described by Kayikcioglu and coauthors mixing trypan blue with sodium hyaluronate. Since profuse anterior chamber irrigation may cause miosis, increasing of intraocular pressure and prolapse of the iris, in this modified technique, instead of washing out the mix, a dispersive viscoelastic agent is injected. This dispersive material composed of sodium chondroitin sulfate 4% and sodium hyaluronate 3% helps to spread the mix over the anterior lens capsule and evacuate it with the bubble air. The rheological

properties of the cohesive and dispersive viscoelastic agents avoid them to be mixed. In such a way, the second agent produces like a Visco anointing of the anterior lens capsule. This technique was used without surgical and postoperative complications.

Assisted cataract surgery femtosecond laser is currently a technique gaining users. However, the high cost of the equipment can be unaffordable for most surgeons. On the other hand, although the new technique claims higher accuracy in achieving perfect capsulorhexis, a few complications such as incomplete capsulotomy, the presence of small anterior capsular tags or even anterior radial tears have been reported [10,11]. This could explain why some surgeons still prefer to dye the anterior capsule to check the outcome of the laser assisted capsulotomy [12].

## References

1. Melles GR, de Waard PW, Pameyer JH, Beckhuis HW (1999) Trypan blue capsule staining to visualize the capsulorhexis in cataract surgery. *J Cataract Refract Surg* 25: 7-9.
2. Werner L, Apple DJ, Crema AS, Izak AM, Pandey SK (2002) Permanent blue discoloration of a hydrogel intraocular lens by intraoperative trypan blue. *J Cataract Refract Surg* 28: 1279-1286.
3. Chowdhury PK, Raj SM, Vasavada AR (2004) Inadvertent staining of the vitreous with trypan blue. *J Cataract Refract Surg* 30: 274-276.
4. Buzard K, Zhang JR, Thumann G, Stripecke R, Sunalp M (2010) Two cases of toxic anterior segment syndrome from generic trypan blue. *J Cataract Refract Surg* 36: 2195-2199.
5. Burkholder B, Srikumaran D, Nanji A, Lee B, Weinberg R (2013) Inadvertent trypan blue posterior capsule staining during cataract surgery. *Am J Ophthalmol* 155: 625-628.
6. Marques DM, Marques FF, Osher RH (2004) Three-step technique for staining the anterior lens capsule with indocyanine green or trypan blue. *J Cataract Refract Surg* 30: 13-16.
7. Giammaria D, Giannotti M, Scopelliti A, Pellegrini G, Giannotti B (2013) Under-air staining of the anterior capsule using Trypan blue with a 30 G needle. *Clin Ophthalmol* 7: 233-235.
8. Yetik H, Devranoglu K, Ozkan S (2002) Determining the lowest trypan blue concentration that satisfactorily stains the anterior capsule. *J Cataract Refract Surg* 28: 988-991.
9. Kayikioğlu Ö, Erakgün T, Güler C (2001) Trypan blue mixed with sodium hyaluronate for capsulorhexis. *J Cataract Refract Surg* 27: 970.
10. Bali SJ, Hodge C, Lawless M, Roberts TV, Sutton G (2012) Early experience with the femtosecond laser for cataract surgery. *Ophthalmology* 119: 891-899.
11. Roberts TV, Lawless M, Bali SJ, Hodge C, Sutton G (2013) Surgical outcomes and safety of femtosecond laser cataract surgery: a prospective study of 1500 consecutive cases. *Ophthalmology* 120: 227-233.
12. Hida WT, Chaves MAPD, Gonçalves MR, Tzeliks PF, Nakano CT, et al. (2014) Comparison between femtosecond laser capsulotomy and manual continuous curvilinear digital image guided capsulorhexis. *Rev Bras Oftalmol* 73: 329-334.