

## Research Article

# Ganglion of the Foot and Ankle: Imaging and Pathological Findings, Differential Diagnosis, and Operative Management

Emrah Sayit<sup>1\*</sup>, Asli Tanrivermis Sayit<sup>2</sup> and Mustafa Bakirtas<sup>3</sup>

<sup>1</sup>Samsun Education and Research Hospital, Department of Orthopaedics and Traumatology, Samsun, Turkey

<sup>2</sup>Samsun Gazi State Hospital, Department of Radiology, Samsun, Turkey

<sup>3</sup>Samsun Education and Research Hospital, Department of Pathology, Samsun, Turkey

### Abstract

Ganglion cysts are the most common benign soft-tissue tumors in the foot and ankle. They are often asymptomatic but can cause discomfort and pain. If they compress the adjacent nerve fascicles, they can cause pain, paresthesias, weakness, muscle denervation, and atrophy. Diagnosis is usually made clinically. Imaging methods such as ultrasound and Magnetic Resonance imaging are also very helpful in making a diagnosis. Treatment is usually conservative. Ganglion cysts can be removed by surgical excision, but surgeons must be careful as these types of cysts are very close to the nerves. The aim in this article is to discuss imaging findings, differential diagnosis, and treatment approaches relating to ganglion cysts in the foot and ankle.

**Keywords:** Foot and Ankle, Ganglion Cysts, Magnetic Resonance Imaging, Ultrasound

### Introduction

Soft tissue tumors of the foot and ankle are relatively rare and include tumor-like lesions and benign and malignant neoplasms. Only approximately 8% of all benign soft tissue lesions and 5% of malignant soft tissue tumors occur in this location [1]. Ganglion cysts are among the most common benign soft-tissue tumors in the foot and ankle [2]. They are often seen in women and younger adults [3]. They are most frequently located around the ankle or at the dorsum of the foot [1]. They are typically thin-walled and may be unilocular or multilocular. They contain a clear, gelatinous fluid [2]. Most of these

**\*Corresponding author:** Emrah Sayit, Samsun Education and Research Hospital, Department of Orthopedics and Traumatology, Barış Blvd, No 199, İlkadım, 55100 Samsun, Turkey, Tel: +90 5056708662; E-mail: dremrahsayit@gmail.com

**Citation:** Sayit E, Sayit AT, Bakirtas M (2015) Ganglion of the Foot and Ankle: Imaging and Pathological Findings, Differential Diagnosis, and Operative Management. J Orthop Res Physiother 1: 005.

**Received:** March 20, 2015; **Accepted:** April 28, 2015; **Published:** May 12, 2015

lesions are smaller than 2 cm [4] and originate from connective tissue, often the joint capsule or tendon sheath but rarely from the meniscus or periosteum [5].

There are many ways of classifying ganglion cysts such as using the relation of structure. The cysts those within the bone are called as intraosseous ganglion cysts, those adjacent to bone called as periosteal ganglion cysts, and those away from bone called as soft tissue ganglion cysts. The cysts those within the joint are called as intra-articular ganglion cysts and those adjacent to a joint called as juxta-articular ganglion cysts [6].

Intraosseous ganglion cysts are benign and often multiloculated lesions located in the subchondral bone [4]. They occur in the mature skeletons of patients and are often seen in the femoral head and the tibia [4]. They are mostly seen at the 4 and 5 decade, and rare at children. The exact pathogenesis of ganglion cysts is still unclear, but they are thought to be the result of acute or repetitive trauma. Most researchers [5,7,8] believe ganglion cysts are due to the myxoid degeneration of surrounding connective tissue, such as the joint capsule or tendon sheath.

The aim in this article is to discuss the imaging findings, differential diagnosis, and treatment approaches relating to ganglion cysts in the foot and ankle.

### Clinical Findings

Most ganglion cysts are asymptomatic, but they can cause discomfort and pain if they become large enough to press on underlying structures [1]. The most common symptoms of ganglion cysts in the foot are pain and footwear problems [3]. Sinus tarsi syndrome or entrapment neuropathy of the posterior tibial also known as tarsal tunnel syndrome can occur due to ganglion cysts in the tarsal sinus or canal [1]. Intraosseous ganglion cysts can cause pain due to the pressure of an expanding intraosseous lesion or a fracture at the periphery of the lesion [4]. An intraneural ganglion cyst is an uncommon occurrence of the peripheral nerves. These cysts can cause compression of the adjacent nerve fascicles, resulting in pain, paresthesias, weakness, muscle denervation, and atrophy [9].

Physical examination can reveal swelling with tenderness. Upon palpation, a cyst can be soft or firm or movable or fixed. A visible lesion is covered with normal skin, which is not red or warm (Figure 1) [4].

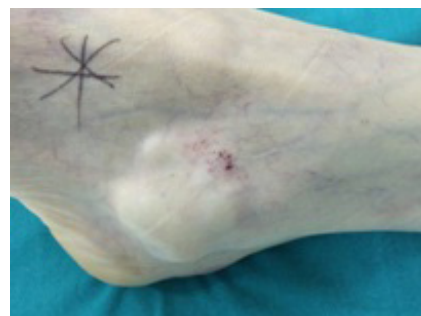
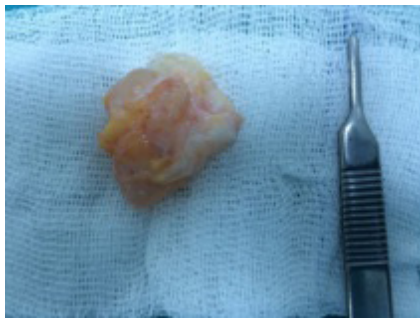
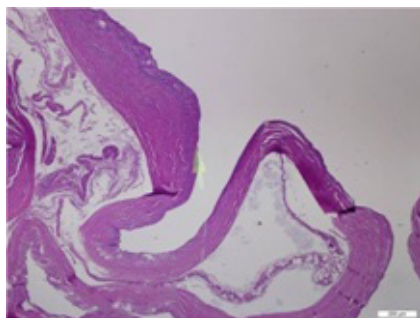
Figure 1: Swelling around the lateral malleolus.

## Pathological Findings

Macroscopically, ganglion cysts appear as a round or oval lesion with multilobulated margins that are filled with mucinous fluid (Figure 2). Pathological findings relating to ganglion cysts include proteinaceous material surrounded by dense fibro-connective tissue without the presence of synovial epithelium when stained with hematoxylin eosin (Figure 3).



**Figure 2:** The lesion was observed as a well-circumscribed, yellowish, lobulated mass upon macroscopic examination.



**Figure 3:** The wall of the ganglion cyst (arrow) is composed of hypocellular fibrous tissue and poor surface epithelium (hematoxylin and eosin staining, x40).

The wall of the ganglion is composed of randomly oriented sheets of collagen arranged in loose layers, one on top of another, and can be shown with electron microscopy. Rare cells are present in the collagen sheets and appear to be fully functional fibroblasts or mesenchymal cells. As no synovial lining exists in these structures, they cannot be classified as true cysts [10]. Although there are focal areas of mucinous degeneration in the cyst wall, significant global degenerative changes, necrosis, or inflammatory changes within the pseudocyst or surrounding tissues have not been demonstrated [10].

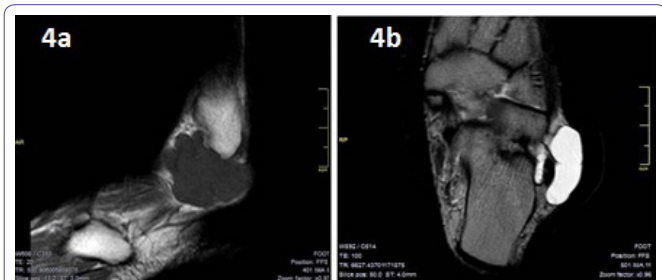
## Imaging Findings

Diagnosis is often made clinically. However, diagnosis of ganglion cysts of the tarsal tunnel and of the plantar aspect of the foot is difficult. A direct X-ray is not useful in the diagnosis of ganglion cysts. However, it is helpful to show bone abnormalities and intraosseous lesions [9]. Upon X-ray, intraosseous ganglion cysts can be seen to be lytic, oval, or circular well-defined lesions in the subchondral area with or without cortical expansion or soft tissue expansion [4]. In addition, ganglion cysts may be in close proximity to osseous structures and can cause erosion due to pressure on the bone [11].

Ultrasound (US) and Magnetic Resonance Imaging (MRI) can differentiate a ganglion cyst from other soft-tissue tumors and tumor-like lesions [2]. US reveals an oval, uniloculated or multiloculated anechoic lesion that had an posterior acoustic

enhancement. If the cysts are complicated by chronic inflammation, infection or hemorrhage, they may have partial or complete hyperechogenic component [12]. However, US is not as good as MRI in showing deeper tissues. Besides, it cannot clearly show the relationship of the lesions with joints and tendon sheaths.

The indications of the MRI are uncertain diagnosis, tarsal tunnel ganglion, planning of the optimal location of the ganglion portal, posterior ankle or plantar ganglion, foot dorsum ganglion that covered the area of the intermetatarsal space and toe pulp ganglion. MRI is also useful in identifying the surrounding neurovascular structures of the lesion, the original site of the tarsal tunnel ganglion, and the relationship between the nerve and the ganglion in order to choose the most appropriate operative management [13]. MRI can also show any deep extension of the foot dorsum ganglion through the intermetatarsal space [14]. Ganglion cysts are shown to be well-defined and hypointense on T1-Weighted (W) images (Figure 4a) and hyperintense on T2-W images (Figure 4b) [9]. Contrast enhancement can reveal septation and cyst walls in post-contrast images [9]. Uncharacteristic signal behavior can be seen when hemorrhages and chronic inflammation develop [11]. Due to chronic inflammation or hemorrhage, the signal intensity increases at T1W images and decreases at T2W images. Besides, thickening and enhancement can be seen at the cyst wall [12].



**Figure 4:** Ganglion cysts in a 49-year-old man: (a) sagittal T1-Weighted (W) spin echo, (b) coronal T2-W turbo spin echo reveals a well-defined, lobulated, multiseptated subcutaneous lesion (arrows) around the lateral malleolus. The lesion demonstrates low T1-W and high T2-W signal intensity. (asterisk: calcaneus).

## Differential Diagnosis

US is helpful in distinguishing cystic lesions from solid lesions. However, it is not sensitive enough to distinguish ganglia from other nerve sheath tumors. MRI is very helpful for the accurate anatomic localization and differential diagnosis of ganglion cysts. An intraneural ganglion cyst is an uncommon occurrence of the peripheral nerves and can cause compression of the adjacent nerve fascicles, resulting in palsies. The most common type is the peroneal intraneural ganglion cyst. In the literature, radial, ulnar, median, sciatic, tibial and posterior interosseous nerve involvements have been reported [15]. Cystic schwannoma, nerve herniation caused by a fascial defect, extraneural ganglion and giant plexiform neurofibromatosis should be considered in the differential diagnosis of intraneural ganglion cysts [9]. Cystic nerve sheath tumors such as schwannoma and extraneural ganglion can be distinguished from cystic intraneural lesions by MRI [15]. Electromyography (EMG) can be performed for the differential diagnosis of a ganglion cyst [9]. The level of palsy, the presence of sensory and motor defects can be detected by EMG.

Also, unicameral bone cysts, chondromyxoid fibroma, Brodie's abscesses, giant cell tumor, fibrous dysplasia, aneurysmal bone cyst,

Differential Diagnosis	Characteristic features of the lesions	Imaging Findings
Aneurysmal bone cyst	They are benign expansile tumour-like bone lesions. They are primarily seen in children and adolescents. They are typically located in the metaphysis of long bones.	Fluid-fluid levels within a aneurysmal bone cysts are best seen on MRI. The cysts are of variable signal intensity, with surrounding rim of low T1 and T2 signal.
Chondroblastoma	They are rare benign cartilaginous neoplasms. They usually originate from the epiphysis of long bones especially humerus. They occurs predominantly in young patients.	X ray shows as a well defined lucent lesions, with either smooth or lobulated margins and a thin sclerotic rim, arising eccentrically in the epiphysis of long tubular bones. Lesions can be seen low to intermediate signal intensity in T1W images and intermediate to high signal intensity in T2W images. Fluid-fluid levels may occasionally be seen.
Pigmented villonodular synovitis	It is a benign inflammatory monoarticular condition of synovium. PVNS is divided into a localised and diffuse form. Localised form is usually extra-articular form of the PVNS. Diffuse form is the most common form of intra-articular disease.	Features are relatively nonspecific in X ray. On CT, the hypertrophic synovium appears as a soft tissue mass. They shows low to intermediate signal intensity in T1W and T2W images with MRI. Also, they shows variable enhancement on contrast enhanced T1W images.

**Table 1:** Differential diagnosis of the ganglion cysts.

chondroblastoma and Pigmented Villonodular Synovitis (PVNS) should be considered in the differential diagnosis of intraosseous ganglion cysts [4,16]. PVNS is a benign proliferative disorder of synovium. It affects joints, bursae and tendon sheath, and may be diffuse or localized. X-ray may be normal. However, in very advanced cases, the synovial proliferation can be seen as uncalcified radiodense mass. Also, bone erosion due to pressure and subchondral cysts are observed. PVNS is seen inhomogeneous signal intensity in MRI according to fat, collagen and hemosiderin it contains. It is frequently seen at hypointense signal intensity on T1 and T2W images, therefore, can be distinguished from the ganglion cyst by the signal intensity which have been shown in T2W images [1]. Giant Cell Tumor (GCT) of bone is well-defined and shows eccentric placement in bone [17]. It often shows close settlement to the articular surface. The epiphyses of the patients are closed. Fluid-fluid levels may be seen at aggressive lesions [17]. GCT of bone and aneurysmal bone cyst can be differentiated from intraosseous ganglion on X-ray by a lack of marginal osteosclerosis and thinning of the adjacent cortex due to expansion [16]. Chondroblastomas show epiphyseal settlement and differential diagnosis of intraosseous ganglion cyst from chondrosarcoma is difficult. At chondroblastoma, marginal osteosclerosis can be seen in X-ray. The differential diagnosis can only be done by lack of enhancement in intraosseous ganglion cyst with contrast enhanced MRI (Table 1) [16].

## Operative Management

The usual treatment is conservative: careful neglect, manual rupture or aspiration. Surgical management is required when the lesion is recurrent or painful [2]. However, resection is associated with a high rate of recurrence (5-30%) [5,14]. High recurrence can be the result of incomplete excision of the cyst wall and unrecognized and incomplete excision of the satellite lesion. The pedicle (connecting the cyst to a nearby synovial joint) must be resected during surgery in order to avoid recurrence, especially for joint-related cysts. Nearby degenerative joint capsules or tendon sheaths should also be removed [2]. Treatment management after recurrence is more difficult than the initial treatment because of increased postoperative pain, high rates of recurrence, and lower patient confidence [2]. Therefore, surgeons must be very careful in determining the initial treatment.

The primary treatment for symptomatic intraosseous ganglion cysts is surgical excision by curettage followed by bone grafting in order to prevent any recurrence and the risk of a collapsing fracture [4].

Arthroscopic removal of ganglion cyst is a less invasive procedure for intraosseous ganglia. Büchler reported no recurrences and

excellent results after arthroscopic treatment. Another advantage of this technique is that the possibility of intervention in the chondral lesions [18].

Nerve damage during excision of the cyst causes major problems. Nerve damage during surgery can be prevented by using a bipolar coagulator and by magnification with a loop [2].

Excision of the tarsal tunnel ganglion is very difficult. Three postoperative tibial nerve injury cases have been reported in the literature [19]. Cutaneous nerve branches, such as the sural nerve and superficial peroneal nerve, are attached to the mass in about one third of cases, requiring meticulous dissection. However, sometimes nerve branches cannot be separated from the mass. In such cases, nerve branches have to be sacrificed after giving the necessary information to the patient [2].

## Conclusion

Ganglion cysts are the most common benign soft-tissue tumors in the foot and ankle. The diagnosis is often easy using imaging methods. However, other cystic tumors of the foot and ankle must be considered in the differential diagnosis of ganglion cysts. Surgeons must be very careful in determining the initial treatment because of the high recurrence rate. Surgeons must also be precise in identifying and protecting the nerves during surgery.

## References

1. Woertler K (2005) Soft tissue masses in the foot and ankle: characteristics on MR Imaging. *Semin Musculoskelet Radiol* 9: 227-242.
2. Ahn JH, Choy WS, Kim HY (2010) Operative treatment for ganglion cysts of the foot and ankle. *J Foot Ankle Surg* 49: 442-445.
3. Macdonald DJ, Holt G, Vass K, Marsh A, Kumar CS (2007) The differential diagnosis of foot lumps: 101 cases treated surgically in North Glasgow over 4 years. *Ann R Coll Surg Engl* 89: 272-275.
4. Sedeek SM, Choudry Q, Garg S (2015) Intraosseous ganglion of the distal tibia: clinical, radiological, and operative management. *Case Rep Orthop* 2015: 759257.
5. Angelides AC, Wallace PF (1976) The dorsal ganglion of the wrist: its pathogenesis, gross and microscopic anatomy, and surgical treatment. *J Hand Surg Am* 1: 228-235.
6. Beaman FD, Peterson JJ (2007). MR imaging of cysts, ganglia, and bursae about the knee. *Radiol Clin North Am* 45: 969-982.
7. Rozbruch SR, Chang V, Bohne WH, Deland JT (1988) Ganglion cysts of the lower extremity: an analysis of 54 cases and review of the literature. *Orthopedics* 21: 141-148.

8. Wu KK (1993) Ganglions of the foot. *J Foot Ankle Surg* 32: 343-347.
9. Nikolopoulos D, Safos G, Sergides N, Safos P (2015) Deep peroneal nerve palsy caused by an extraneural ganglion cyst: a rare case. *Case Rep Orthop* 2015: 861697.
10. Loder RT, Robinson JH, Jackson WT, Allen DJ (1988) A surface ultrastructure study of ganglia and digital mucous cysts. *J Hand Surg AM* 13: 758-762.
11. Weishaupt D, Treiber K, Kundert HP, Zollinger H, Vienne P, et al. (2003) Morton neuroma: MR imaging in prone, supine, and upright weight-bearing body positions. *Radiology* 226: 849-856.
12. Hul EV, Vanhoenacker F, Dyck PV, Schepper AD, Parizel PM (2011) Pseudotumoural soft tissue lesions of the foot and ankle: a pictorial review. *Insights Imaging* 2: 439-452.
13. Lui TH (2014) Arthroscopic ganglionectomy of the foot and ankle. *Knee Surg Sports Traumatol Arthrosc* 22: 1693-1700.
14. McEvedy BV (1962) Simple ganglia. *Br J Surg* 49: 585-594.
15. Patel P, Schucany WG (2012) A rare case of intraneural ganglion cyst involving the tibial nerve. *Proc (Bayl Univ Med Cent)* 25: 132-135.
16. Sakamoto A, Oda Y, Iwamoto Y (2013) Intraosseous Ganglia: A Series of 17 Treated Cases. *Biomed Res Int* 2013: 462730.
17. Chakarun CJ, Forrester DM, Gottsegen CJ, Patel DB, White EA, et al. (2013). Giant cell tumor of bone: review, mimics, and new developments in treatment. *Radiographics* 33: 197-211.
18. Büchler L, Hosalkar H, Weber M (2009) Arthroscopically Assisted Removal of Intraosseous Ganglion Cysts of the Distal Tibia. *Clin Orthop Relat Res* 467: 2925-2931.
19. Rosson GD, Spinner RJ, Dellon AL (2005) Tarsal tunnel surgery for treatment of tarsal ganglion: a rewarding operation with devastating potential complications. *J Am Podiatr Med Assoc* 95: 459-463.