



## Research Article

# Treatment of Mayer Rokitansky Kuster Hauser's Syndrome in Senegal

Abdoul Aziz Diouf<sup>1\*</sup>, Moussa Diallo<sup>1</sup>, Khalifa Ababacar Gueye<sup>1</sup>, Fatima Ezzahra Echouraf<sup>1</sup>, Mame Diarra Ndiaye<sup>2</sup>, Aminata Niass<sup>1</sup>, Codou Sene<sup>1</sup>, Anna Dia<sup>1</sup> and Alassane Diouf<sup>1</sup>

<sup>1</sup>Department of Obstetrics and Gynecology, Pikine National Hospital Center, Thiaroye Pikine, Dakar, Senegal

<sup>2</sup>Gynecological and Obstetric Clinic, Aristide Le Dantec Hospital, Dakar, Senegal

### Abstract

**Objective:** To determine the effect of the Dupuytren technique and Frank's method on four patients.

**Materials and methods:** This was a study of clinical case series collected between 2016 and 2020 at the National Hospital Center of Pikine in Dakar-Senegal.

**Results:** We report four cases of young patients with late diagnosis MRKH syndrome. Difficulty in sexual intercourse and infertility were the main reasons for consultation. Ultrasound guided the diagnosis and MRI confirmed it. Laparoscopy made it possible to objectify the absence of a uterus and the associated lesions, but also to guide the vaginoplasty. On the therapeutic step, two patients received surgical treatment according to the Dupuytren technique and one patient received non-surgical treatment according to Frank's method. The fourth was advised to continue intercourse, as she had already achieved a vaginal length of 7 cm with this procedure.

The result of this treatment made it possible to go from a vaginal length of 1 cm to 9 cm on average for the Dupuytren method and from 2 cm to 7 cm for the Frank method. All of our patients were sexually satisfied.

**Conclusion:** The diagnosis of MRKH syndrome is late in our countries. The Dupuytren technique appears effective if the vaginal

\*Corresponding author: Abdoul Aziz Diouf, Department of Obstetrics and Gynecology, Pikine National Hospital Center, Thiaroye Pikine, Dakar, Senegal, Tel: +33 8530071; Fax: +33 8530069; E-mail: dizezfr@yahoo.fr

**Citation:** Diouf AA, Diallo M, Gueye KA, Echouraf FE, Ndiaye MD, et al. (2021) Treatment of Mayer Rokitansky Kuster Hauser's Syndrome in Senegal. J Reprod Med Gynecol Obstet 6: 067.

**Received:** January 14, 2021; **Accepted:** January 26, 2021; **Published:** February 02, 2021

**Copyright:** © 2021 Diouf AA, et al. This is an open-access article distributed under the terms of the Creative Commons Attribution License, which permits unrestricted use, distribution, and reproduction in any medium, provided the original author and source are credited.

depth is less than 2 cm, and the Frank method should suffice when it is greater than 2 cm.

**Keywords:** Genital malformation; Mayer-rokitansky-kuster-hauser; Neovagina; Vaginal agenesis

### Introduction

The Mayer-Rokitansky-Kuster-Hauser syndrome (MRKH) or Müllerian aplasia is a rare congenital condition characterized by the absence of a uterus and the upper two-thirds of the vagina in women with normally developed secondary sexual characteristics. This condition affects approximately 1 in 4,500 women [1]. The discovery of MRKH syndrome is almost always made in adolescence by a painless primary amenorrhea in a young girl with completely normal puberty development [2]. The objective of this study was to determine the effect of the Dupuytren technique and Frank's method on four patients aged 19 to 28 with MRKH syndrome in the period from 2016 to 2020 at the National Center Hospital of Pikine in Dakar-Senegal.

### Methodology

This was a series of clinical cases enrolled over a period of 4 years (From 2016 to 2020). The study took place in the Gynecology Department of the National Hospital Center of Pikine. The patients were recruited during gynecological consultations. Each patient underwent a comprehensive exam with questioning about amenorrhea, sexual activity and infertility, a physical exam looking for secondary sex characteristics and measuring the length of the vagina. Regarding paraclinical examinations, a pelvic ultrasound or an MRI was requested. Other examinations such as laparoscopy and karyotype were performed depending on the context. The diagnosis was made in the absence of visualization of the uterus and the upper 2/3 of the vagina on MRI after ultrasound orientation.

### Observations

The average age of our patients was 22.6 years with extremes of 19 and 28 years. The reason for consultation was the impossibility of sexual intercourse since marriage for 3 patients and primary infertility for the fourth (Table 1). The interrogation also revealed a primary amenorrhea which had not justified a consultation in Gynecology. One patient reported cyclic pelvic pain. No specific medical history was reported in our series. The clinical examination found good general condition in all cases. The secondary sexual characteristics were present and were normal (Figures 1 and 2). Pelvic examination revealed a one-eyed vagina with depths of 1cm, 2cm, 3cm and 7cm respectively. A pelvic ultrasound systematically performed in all of our patients confirmed the absence of a uterus.

Other additional examinations were requested depending on financial means. It was MRI (Figure 3) in 3 cases, diagnostic laparoscopy (Figure 3) in 3 cases and karyotype in 1 case. All these examinations confirmed the diagnosis of MRKH syndrome, with an

absence of vagina and uterus, although the appendages were present. One case was associated with a urinary malformation of the pelvic kidney type. The karyotype was type 46XX for all three patients.

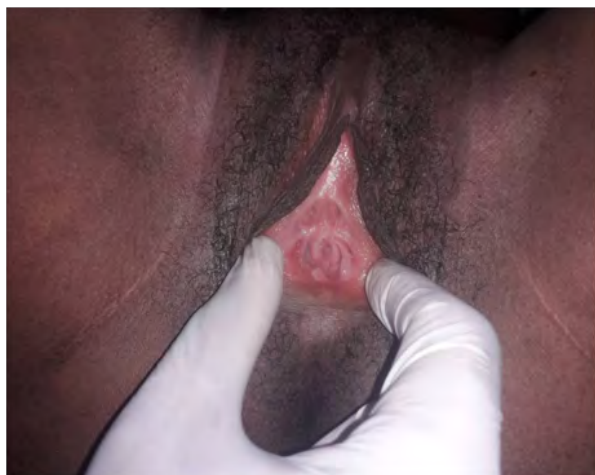


Figure 1: Vaginal agenesis before specific treatment (patient 3).

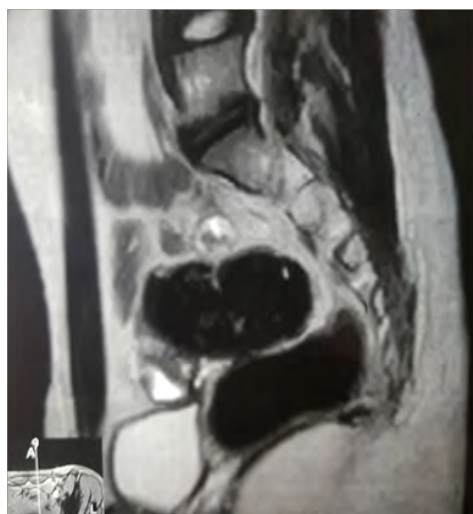

Figure 2: MRI profile section showing absence of the uterus with visible presence of two ovaries (Patient 3).

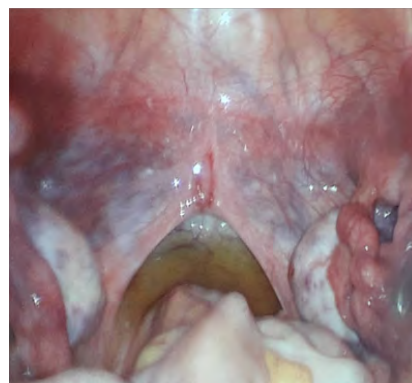

Figure 3: Laparoscopic aspect showing the absence of uterus and presence of ovaries (Patient 3).

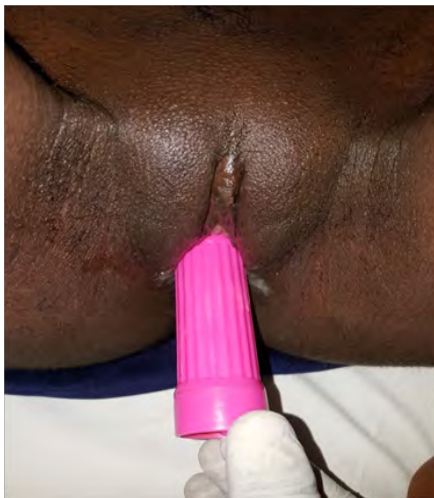
Two patients had undergone enlargement surgery using the Dupuytren technique (Figure 4). Another patient chose non-surgical treatment with progressive vaginal dilation using Frank's method. The fourth was advised to continue intercourse, as she had already achieved a vaginal length of 7 cm with this procedure. Psychosexual follow-up was provided by the surgical team. These different treatments had made it possible to obtain, within 5 months, a vaginal length of 9 cm on average for the Dupuytren method (Figure 5) and 7 cm for the Frank method. Sexual satisfaction was noted by all patients. Infertility, however, remained a major concern in current follow-up.



Figure 4: Macroscopic appearance of the vaginal fund during enlargement vaginoplasty properly presenting to specific Dupuytren technique (patient 3).

Patient	Age (years)	Country	Marital status	Functional signs	Diagnostic methods	Treatment	Results: Vagina depth (cm)	Sexual satisfaction
Patient 1	28	Mauritania	Married	Primary amenorrhea Primary infertility	MRI	Psychological care	7	Yes
Patient 2	19	Guinea	Divorced	Primary amenorrhea Inability to have sex	MRI Laparoscopy	Dupuytren method	8	Yes
Patient 3	21	Senegal	Married	Primary amenorrhea Inability to have sex	Pelvic ultrasound MRI Laparoscopy	Dupuytren method	10	Yes
Patient 4	21	Senegal	Divorced	Primary amenorrhea Inability to have sex	Pelvic ultrasound Laparoscopy	Frank method	8	Yes

Table 1: Summary of cases of MRKH syndromes treated at the pikine national hospital center.



**Figure 5:** Vaginal dilation session in 2 considered months after enlargement vaginoplasty (patient 3).

## Discussion

### Frequency

The Mayer-Rokitansky-Kuster-Hauser syndrome (MRKH) or Müllerian aplasia is a rare congenital condition with a frequency of 1 in 5,000 female newborns. Its onset is generally sporadic although a few familial cases have been described [3-5]. Its incidence in Africa and Senegal is not specified due to poor documentation. In our Hospital, during the 4 years of study, we identified 4 cases, or one case per year. Our results are similar to those of Schwaab and Bryand in 2019 [6], who over a period of 17 years, had identified 31 cases, or 1.8 cases per year.

### Clinical aspects

The reasons for consultation in our series were the impossibility of intercourse and primary infertility. Primary amenorrhea is the earliest clinical sign [1,7], but in our context where adolescent sexuality is rarely discussed or even taboo, patients do not come for a consultation until after marriage. The inexpensive abdominal ultrasound remains the diagnostic test of choice. The study by Schwaab and Bryand, in 2019 [6] showed the place of ultrasound in the management of Rokitansky Syndrome by comparing it to MRI; no ultrasound results were misdiagnosed. However, MRI remains the gold standard in diagnosis. It makes it possible to confirm the malformation and also to find the associated anomalies [8,9].

The diagnostic laparoscopy was performed in three of our patients, it confirmed the diagnosis as well as the associated lesions but also guided the Dupuytren enlargement vaginoplasty. Laparoscopy is a minimally invasive examination that should only be performed in cases where the ultrasound and MRI are inconclusive, or with the aim of involving additional procedures.

### Therapeutic aspects

In our series, two patients had received surgical management according to Dupuytren. This technique consists in performing spontaneous epithelialization on a mold, after having created a

neocavity [10]. It is followed by sessions of progressive dilation until healing allows for sexual intercourse. The epithelialization took two months for our patients. It requires good support and personal motivation from the patient.

The vaginal depth that we obtained with this technique is greater than that reported by Ben Hmid et al., [11] who used the techniques of Mac Indoe and Davydov [12,13] in 13 patients and who had obtained an average of 7 cm (from 4.5 cm to 10 cm). The difference in these results could be explained by the fact that in the series by Ben Hmid et al., some patients did not have regular sexual intercourse after the treatment. Mac Indoe's technique is considered the Gold standard for vaginal aplasia, due to its simplicity and low risk of complications [14]. On the other hand, the techniques of Dupuytren and Davydov also have the same success and have the advantage of making the precise diagnosis and of detecting the associated lesions thanks to laparoscopy.

In one patient, only Frank's method was used, it is a non-surgical method, using pyrex prostheses. This technique therefore involves the use of passive dilation of the vaginal cup. It allowed to have a vaginal depth of 7 cm after 3 months of treatment. However, it should be emphasized that this technique requires compliance and significant attendance on the part of the patient. In addition, the vaginal cup must be deep enough (2 to 4 cm) to allow dilation to begin [15]. Some authors, especially North Americans, as well as the American College of Obstetrics and Gynecology, recommend this non-surgical technique as a first-line treatment for the treatment of aplasia [16,17]. The procedure can last six weeks to several months, with varying success rates. Functionally, all of our patients reported sexual satisfaction after treatment. We also note the satisfaction of two spouses who actively participated in the support and care.

## Conclusion

Our first experience, which we retain through these 4 cases of patients with MRKH syndrome, is the problem of announcing the diagnosis and its consequence on fertility, sexual disorders and the choice of therapy. The Dupuytren technique appears effective if the vaginal depth is less than 2 cm, and the Frank method should suffice when it is greater than 2 cm.

## Availability of Data and Materials

The datasets used and/or analysed during the current study are available from the corresponding author on reasonable request.

## Competing Interests

The authors declare that they have no competing interests.

## References

1. Morcel K, Guerrier D, Watrin T, Pellerin I, Levêque J (2008) Le syndrome de Mayer-Rokitansky-Küster-Hauser (MRKH): Clinique et génétique. *J Gyn Obst Biol Repro* 37: 539-546.
2. Reindollar RH, Byrd JR, McDonough PG (1981) Delayed sexual development: A study of 252 patients. *Am J Obstet Gynecol* 140: 371-380.
3. Azoury RS, Jones HW Jr (1966) Cytogenetic findings in patients with congenital absence of the vagina. *Am J Obstet Gynecol* 94: 178-180.
4. Griffin JE, Edwards C, Madden JD, Harrod MJ, Wilson JD (1976) Congenital absence of the vagina. The Mayer-Rokitansky-Kuster-Hauser syndrome. *Ann Intern Med* 85: 224-236.

5. Carson SA, Simpson JL, Malinak LR, Elias S, Gerbie AB, et al. (1983) Heritable aspects of uterine anomalies. II. Genetic analysis of Müllerian aplasia. *Fertil Steril* 40: 86-90.
6. Schwaab T, Bryand A (2019) [Place of ultrasound in the management of Mayer-Rokitansky-Kuster-Hauser syndrome. Observational study from 2000 to 2017 within university hospital of Strasbourg]. *Gynecol Obstet Fertil Senol* 47: 783-789.
7. Oppelt P, Renner SP, Kellermann A, Brucker S, Hauser GA, et al. (2006) Clinical aspects of Mayer-Rokitansky-Kuester-Hauser syndrome: Recommendations for clinical diagnosis and staging. *Hum Reprod* 21: 792-797.
8. Maubon A, Ferru JM, Courtieu C, Mares P, Rouanet JP (1996) [Gynecological malformations. Classification and contribution of different imaging methods]. *J Radio* 77: 465-475.
9. Carrington BM, Hricak H, Nuruddin RN, Secaf E, Laros RK Jr, et al. (1990) Müllerian duct anomalies: MR imaging evaluation. *Radiology* 176: 715-720.
10. Bianchi S, Frontino G, Ciappina N, Restelli E, Fedele L (2011) Creation of a neovagina in Rokitansky syndrome: Comparison between two laparoscopic techniques. *Fertil Steril* 95: 1098-1104.
11. Hmid RB, Touhami O, Zouaoui B, Amara FB, Zghal D, et al. (2012) [Evaluation of different techniques for vaginoplasty in the treatment of Mayer-Rokitansky-Kuster-Hauser syndrome]. *Tunis Med* 90: 852-855.
12. Bekerecioglu M, Balat O, Tercan M, Karakok M, Ugur MG, et al. (2008) Adaptation process of the skin graft to vaginal mucosa after McIndoe vaginoplasty. *Arch Gynecol Obstet* 277: 551-554.
13. Davydov SN, Zhvitiashvili OD (1974) Formation of vagina (colpopoiesis) from peritoneum of Douglas pouch. *Acta Chir Plast* 16: 35-41.
14. Alessandrescu D, Peltecu GC, Buhimschi CS, Buhimschi IA (1996) Neocolpopoiesis with split-thickness skin graft as a surgical treatment of vaginal agenesis: Retrospective review of 201 cases. *Am J Obstet Gynecol* 175: 131-138.
15. Frank T (1938) The formation of an artificial vagina without operation. *Am J Obstet Gynecol* 35: 1053-1055.
16. Roberts CP, Haber MJ, Rock JA (2001) Vaginal creation for müllerian agenesis. *Am J Obstet Gynecol* 185: 1349-1353.
17. Edmonds DK (2003) Congenital malformations of the genital tract and their management. *Best Pract Res Clin Obstet Gynaecol* 17: 19-40.





- Advances In Industrial Biotechnology | ISSN: 2639-5665
- Advances In Microbiology Research | ISSN: 2689-694X
- Archives Of Surgery And Surgical Education | ISSN: 2689-3126
- Archives Of Urology
- Archives Of Zoological Studies | ISSN: 2640-7779
- Current Trends Medical And Biological Engineering
- International Journal Of Case Reports And Therapeutic Studies | ISSN: 2689-310X
- Journal Of Addiction & Addictive Disorders | ISSN: 2578-7276
- Journal Of Agronomy & Agricultural Science | ISSN: 2689-8292
- Journal Of AIDS Clinical Research & STDs | ISSN: 2572-7370
- Journal Of Alcoholism Drug Abuse & Substance Dependence | ISSN: 2572-9594
- Journal Of Allergy Disorders & Therapy | ISSN: 2470-749X
- Journal Of Alternative Complementary & Integrative Medicine | ISSN: 2470-7562
- Journal Of Alzheimers & Neurodegenerative Diseases | ISSN: 2572-9608
- Journal Of Anesthesia & Clinical Care | ISSN: 2378-8879
- Journal Of Angiology & Vascular Surgery | ISSN: 2572-7397
- Journal Of Animal Research & Veterinary Science | ISSN: 2639-3751
- Journal Of Aquaculture & Fisheries | ISSN: 2576-5523
- Journal Of Atmospheric & Earth Sciences | ISSN: 2689-8780
- Journal Of Biotech Research & Biochemistry
- Journal Of Brain & Neuroscience Research
- Journal Of Cancer Biology & Treatment | ISSN: 2470-7546
- Journal Of Cardiology Study & Research | ISSN: 2640-768X
- Journal Of Cell Biology & Cell Metabolism | ISSN: 2381-1943
- Journal Of Clinical Dermatology & Therapy | ISSN: 2378-8771
- Journal Of Clinical Immunology & Immunotherapy | ISSN: 2378-8844
- Journal Of Clinical Studies & Medical Case Reports | ISSN: 2378-8801
- Journal Of Community Medicine & Public Health Care | ISSN: 2381-1978
- Journal Of Cytology & Tissue Biology | ISSN: 2378-9107
- Journal Of Dairy Research & Technology | ISSN: 2688-9315
- Journal Of Dentistry Oral Health & Cosmesis | ISSN: 2473-6783
- Journal Of Diabetes & Metabolic Disorders | ISSN: 2381-201X
- Journal Of Emergency Medicine Trauma & Surgical Care | ISSN: 2378-8798
- Journal Of Environmental Science Current Research | ISSN: 2643-5020
- Journal Of Food Science & Nutrition | ISSN: 2470-1076
- Journal Of Forensic Legal & Investigative Sciences | ISSN: 2473-733X
- Journal Of Gastroenterology & Hepatology Research | ISSN: 2574-2566
- Journal Of Genetics & Genomic Sciences | ISSN: 2574-2485
- Journal Of Gerontology & Geriatric Medicine | ISSN: 2381-8662
- Journal Of Hematology Blood Transfusion & Disorders | ISSN: 2572-2999
- Journal Of Hospice & Palliative Medical Care
- Journal Of Human Endocrinology | ISSN: 2572-9640
- Journal Of Infectious & Non Infectious Diseases | ISSN: 2381-8654
- Journal Of Internal Medicine & Primary Healthcare | ISSN: 2574-2493
- Journal Of Light & Laser Current Trends
- Journal Of Medicine Study & Research | ISSN: 2639-5657
- Journal Of Modern Chemical Sciences
- Journal Of Nanotechnology Nanomedicine & Nanobiotechnology | ISSN: 2381-2044
- Journal Of Neonatology & Clinical Pediatrics | ISSN: 2378-878X
- Journal Of Nephrology & Renal Therapy | ISSN: 2473-7313
- Journal Of Non Invasive Vascular Investigation | ISSN: 2572-7400
- Journal Of Nuclear Medicine Radiology & Radiation Therapy | ISSN: 2572-7419
- Journal Of Obesity & Weight Loss | ISSN: 2473-7372
- Journal Of Ophthalmology & Clinical Research | ISSN: 2378-8887
- Journal Of Orthopedic Research & Physiotherapy | ISSN: 2381-2052
- Journal Of Otolaryngology Head & Neck Surgery | ISSN: 2573-010X
- Journal Of Pathology Clinical & Medical Research
- Journal Of Pharmacology Pharmaceutics & Pharmacovigilance | ISSN: 2639-5649
- Journal Of Physical Medicine Rehabilitation & Disabilities | ISSN: 2381-8670
- Journal Of Plant Science Current Research | ISSN: 2639-3743
- Journal Of Practical & Professional Nursing | ISSN: 2639-5681
- Journal Of Protein Research & Bioinformatics
- Journal Of Psychiatry Depression & Anxiety | ISSN: 2573-0150
- Journal Of Pulmonary Medicine & Respiratory Research | ISSN: 2573-0177
- Journal Of Reproductive Medicine Gynaecology & Obstetrics | ISSN: 2574-2574
- Journal Of Stem Cells Research Development & Therapy | ISSN: 2381-2060
- Journal Of Surgery Current Trends & Innovations | ISSN: 2578-7284
- Journal Of Toxicology Current Research | ISSN: 2639-3735
- Journal Of Translational Science And Research
- Journal Of Vaccines Research & Vaccination | ISSN: 2573-0193
- Journal Of Virology & Antivirals
- Sports Medicine And Injury Care Journal | ISSN: 2689-8829
- Trends In Anatomy & Physiology | ISSN: 2640-7752

Submit Your Manuscript: <https://www.heraldopenaccess.us/submit-manuscript>