

Case Report

Hepatic Portal Venous Gas in a Patient Submitted to Percutaneous Gastrostomy: Case Report and Literature Review

Luiz Carlos de Araújo Souza^{1*}, Carlos Hirokatsu Watanabe Silva², Oliver Rojas Claros³ and Rafael Francisco Alves Silva⁴

¹Researcher of the Department of Cytopathology and Pathological Anatomy of the Base Institute of the Federal District (NUCAP-IHBDF), St. Hospital Medical South - Asa Sul, Brasília, Brazil

²Physician Urologist - Department of Uro-Oncology of Hospital Santa Lúcia (HSL), Brasília, Brazil

³Physician Surgeon of the Hospital Israelita Albert Einstein (HIAE), São Paulo, Brazil

⁴Undergraduates of Medicine in the University Center of Brasília (UniCEUB), Brasília Brazil

Abstract

Introduction: Hepatic Portal Venous Gas (HPVG) is a rare condition associated with several pathological conditions that can evolve with high morbidity.

Presentation of Case: A 89-year-old female patient who needed hospitalization for pneumonia and intestinal constipation. The patient used antibiotic therapy with piperacillin and tazobactam for pneumonia but evolved with *Enterococcus* cystitis. Due to the difficulty of motor rehabilitation and deglutition, they chose to perform a percutaneous endoscopic gastrostomy. After two days, the patient presented diffuse abdominal pain, abdominal distension, nausea, vomiting, tachycardia, hypotension, without signs of peritonitis. Laboratory tests showed leukocytosis (15.570 leukocytes /mm³), C-reactive protein (166 mg/dl) and worsening of renal function (1.4 mg/dl). Computed Tomography (CT) revealed abdominal HPVG and small pneumoperitoneum near the area of gastrostomy. After clinical deterioration with septic shock, they opted for an exploratory laparotomy that showed cloudy ascites and the gastrostomy was well positioned, with no signs of leakage into the cavity. Despite the intensive support, the patient evolved with multiple organ failure and death.

***Corresponding author:** Luiz Carlos de Araújo Souza, Researcher of the Department of Cytopathology and Pathological Anatomy of the Base Institute of the Federal District (NUCAP-IHBDF), St. Hospital Medical South - Asa Sul, Brasília, Brazil, Tel: +55 61999232232; Email: luiz_carlos5@hotmail.com

Citation: Souza LCA, Silva CHW, Claros OR, Silva RFA (2019) Hepatic Portal Venous Gas in a Patient Submitted to Percutaneous Gastrostomy: Case Report and Literature Review. J Surg Curr Trend Innov 3: 010

Received: January 30, 2019; **Accepted:** February 08, 2019; **Published:** February 25, 2019

Copyright: © 2019 Souza LCA, et al. This is an open-access article distributed under the terms of the Creative Commons Attribution License, which permits unrestricted use, distribution, and reproduction in any medium, provided the original author and source are credited.

Discussion and Conclusion: HPVG is a rare radiological signal associated with severe underlying pathological conditions in need of early intervention. With the ease of CT abdomen, the diagnosis of HPVG is increasing, so it is up to the surgeon to indicate the operative procedure when this is necessary, especially when there is evidence of intestinal ischemia.

Keywords: Computed tomography abdomen; Hepatic portal venous gas; Percutaneous endoscopic gastrostomy

Introduction

Hepatic Portal Venous Gas (HPVG) is a rare condition, first described by Wolfe and Nevins (1955) in neonates with Necrotizing Enterocolitis (NEC). Scientific work has shown that this pathology is associated with several pathological conditions of high morbidity, requiring rapid and effective treatment [1,2].

Liebman et al., in describing the diseases most commonly associated with HPVG determined that intestinal necrosis (72%), followed by ulcerative colitis (8%), intra abdominal abscess (6%), small bowel obstruction and gastric ulcer (3%) are the most associated, explaining the high mortality rate (56%-90%) reported in association with HPVG [3-5].

The physiopathology for the onset of HPVG is not well elucidated. The main factors that predispose the portal venous system to gas accumulation include: The escape of gas produced by gas-forming organisms in the intestinal lumen or in an abscess circulating in the liver or the presence of gas-forming organisms in the venous system with gas passage to the circulation [3].

One of the main methods for the diagnostic elucidation of HPVG is simple abdominal radiography, ultrasonography, color Doppler flow or Computed Tomography (CT). In this case, one of the main characteristic findings on abdominal plain is a branching radiolucency extending to within 2cm beneath the liver capsule [6].

With the advent of CT, the identification of intestinal pneumatosis became an important sign in the diagnosis of patients with intestinal ischemia justifying HPVG [7]. CT as well as other imaging tests help in the decision making regarding the need for a surgical approach when associated with clinical evaluation data. As most cases are associated with intestinal ischemia, surgical exploration is often necessary, especially in the presence of intestinal pneumatosis [7].

In this work we present a case report of HPVG in a patient undergoing percutaneous gastrostomy.

Presentation of Case

A 89-year-old female patient admitted to the ward of neurology due to a cerebrovascular accident in the middle cerebral artery. As background, the patient had intermittent controlled atrial fibrillation, heart failure and left internal carotid artery stenosis. During hospitalization, the Patient presented pneumonia on day 7 and intestinal constipation resolved with glycerin clister. At the end of the antibiotic

Therapy with piperacillin and tazobactam for pneumonia on the 14th day of hospitalization. On the 17th day of hospitalization, the Patient presented Vancomycin-sensitive *Enterococcus* stitis. On the 21st day of hospital stay, after resolution of the pulmonary infection, the patient presented good general condition and due to the difficulty of motor rehabilitation and swallowing, chosen for percutaneous endoscopic gastrostomy.

Two days after the gastrostomy, the Patient had abdominal distention, nausea and vomiting. At the evaluation of the surgery team, the Patient complained of diffuse abdominal pain, was tachycardic and hypotensive (Blood pressure: 96x60 mmhg). At physical examination, diffuse abdominal pain, worse in the hypogastroregion, without signs of peritonitis. Laboratory tests showed leukocytosis (15.570 leukocytes /mm³), C-reactive protein: 166 mg/dl (previous 16 mg/dl) and worsening of renal function (acute renal failure, creatinine of 0.81 mg/dl initial evolving to 1.4 mg/dl).

After performing abdominal CT that showed HPVG and small pneumoperitoneum near the area of gastrostomy. Considering CT findings (Figure 1) and clinical deterioration with septic shock, we chose exploratory laparotomy in view of possible intestinal ischemia/peritonitis. The exploratory laparotomy was found to be turbidascitic fluid in small amount that was sent to culture. The gastrostomy was well positioned, with no signs of leakage into the cavity. No lesions were found in intestinal loops or lesions of abominable viscera. In the postoperative follow-up, there was a progressive worsening of the septic shock with need for vasoactive drugs in the first post operative day.

Maintain edonmechanical ventilation and anti biotic therapy with meropenem and vancomycin since the surgical procedure.

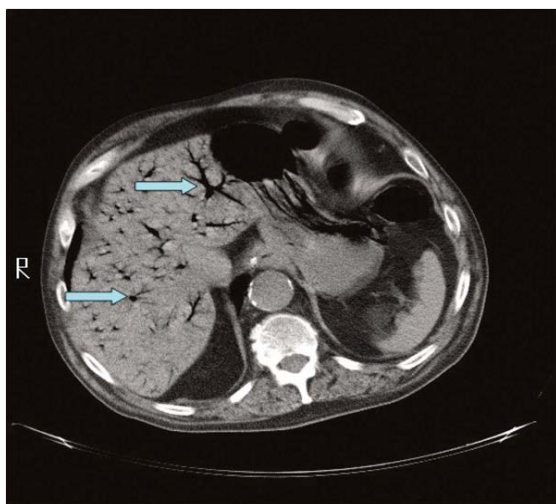


Figure 1: Computed tomography of the abdomen, the blue colored arrows identify and shows the hepatic portal venous gas.

After isolating cultures from the onset of the carbapenem sensitive *Proteus mirabilis* epticum and the ascitic fluid culture collected at the operative procedure, it isolated vancomycin-sensitive *Staphylococcus aureus*. On the 6th post operative day, the patient did not receive surgical indications for surgical re-placement, since the gastrostomy was well positioned, with no signs of cavity leakage and

lesion was found in intestinal loops or lesions of abominable viscera. On the 6th postoperative day, the patient evolved with multiple organ failure and death, despite the intensive support.

Discussion

In relation to the patho physiological mechanisms of HPVG, there are two main mechanisms demonstrated in animal model: The first consists of the passage of gas under pressure from the lumen of the intestines to the portal venous circulation, the second consists of the passage of gas into the portal circulation by changes in intestinal mucosa, which could justify the passage of air to the portal circulation in cases of gastric ulcers [7]. A third theory would be the production of gas by bacteria associated or not with pileflebite [6,7].

HPVG occurs mainly in cases of intestinal ischemia but may also be due to sepsis, inflammatory bowel disease, diverticulitis, gastric dilatation, abdominal trauma, catheter insertion for jejunostomy, laparoscopic percutaneous gastrostomy, esophageal variceal ligation, pancreatitis acute [7]. Several other associated conditions have been described and, according to Abboud et al., any of these conditions can lead to intestinal hypo perfusion and subsequent ischemia [6]. Adynamic ileus would also play an important role, as it would facilitate bacterial proliferation and loosening of the loops. Increased intra-luminal pressure of the intestinal loops would allow the passage of gas and bacterial translocation to the portal system through lesions of the intestinal mucosa [6].

In the only case report of HPVG after endoscopic gastrostomy previously published, the author attributed the presence of air in the portal circulation to gastric mucosal lesion that associated with gastro paresis, ileus and distension of loops secondary to leakage of gastrostomy to peritoneal cavity allowed bacterial translocation to the portal system [7].

In our case, we did not show signs of gastrostomy leakage, intestinal ischemia, or even distension of loops in exploratory laparotomy. We believe that the HPVG picture may be secondary to a set of factors and not only to the endoscopic procedure. The presence of multiple comorbidities, the state of splanchnic and mesenteric hypoperfusion associated with pulmonary and urinary infectious pictures, even in antibiotic therapy, would lead to the state of immunosuppression. The percutaneous gastrostomy and the gastric distension resulting from the endoscopic procedure would have led to a portal bacterial translocation that would contribute to the worsening of the septic condition in a patient already debilitated by the previous conditions, determining the poor prognosis.

Even in the absence of signs of intestinal ischemia to the surgical procedure, it is probable that there was already relative intestinal ischemia. Since the Patient had evidence of macrovascular attherosclerotic disease in the carotid and coronary territories, it is probable that she already had mesenteric arteriopathy. The hypoperfusion profile secondary to infectious events could lead to non-obvious intestinal ischemia and surgical evaluation, since initially the ischemic lesion occurs at the mucosal level.

Abboud et al., emphasizes the importance of the clinical events underlying HPVG and the coexistence of chronic diseases that could lead to immunological dysfunction and changes in the intestinal microbiota [6]. In the past, the presence of HPVG was almost always associated with conditions of high mortality and in need of surgical

treatment in the context of mesenteric ischemia [3]. However, the advancement of imaging studies has allowed the diagnosis of HPVG in increasingly early stages of intestinal ischemia and in conditions in which surgical treatment is not necessary [6].

It is evident that the presence of HPVG is related to serious conditions, which in spite of the necessity of the operative treatment must be known to the surgeon. The surgeon should keep in mind that the presence of air in the port system does not necessarily determine the poor prognosis. However, in the presence of HPVG, the underlying pathological conditions should be part of the diagnostic reasoning and clinical support is often the difference in the success of the treatment of these patients.

Conclusion

HPVG is a radiological signal that should always lead the surgeon to seek serious underlying pathological conditions in need of early intervention. The surgeon should indicate an operative procedure when this is necessary, especially when there is evidence of intestinal ischemia. However, the surgeon should know that the presence of HPVG alone does not indicate a worse prognosis. The careful evaluation of the underlying conditions will dictate the best treatment, surgical or not.

Disclosures and Ethics

The case report followed the ethical precepts, analyzed the data in a confidential way by the research team and the results will not allow the identification of study participants.

Source of Financing

The author(s) received no financial support for the research, authorship, and/or publication of this article.

Conflict of Interests

The author(s) declared no potential conflicts of interest with respect to the research, authorship, and/or publication of this article.

References

1. Thompson AM, Bizzarro MJ (2008) Necrotizing enterocolitis in newborns: Pathogenesis, prevention and management. *Drugs* 68: 1227-1238.
2. Merritt CR, Goldsmith JP, Sharp MJ (1984) Sonographic detection of portal venous gas in infants with necrotizing enterocolitis. *AJR Am J Roentgenol* 143: 1059-1062.
3. Liebman PR, Patten MT, Manny J, Benfeld JR, Hechtman HB (1978) Hepatic-portal venous gas in adults: Etiology, pathophysiology and clinical significance. *Ann Surg* 187: 281-287.
4. Sellner F, Sobhian B, Baur M, Sellner S, Horvath B, et al. (2007) Intermittent hepatic portal vein gas complicating diverticulitis--a case report and literature review. *Int J Colorectal Dis* 22: 1395-1399.
5. Muscari F, Suc B, Lagarrigue J (1999) [Hepatic portal venous gas: Is it always a sign of severity and surgical emergency?] *Chirurgie* 124: 69-72.
6. Abboud B, Hachem JE, Yazbeck T, Doumit C (2009) Hepatic portal venous gas: Physiopathology, etiology, prognosis and treatment. *World J Gastroenterol* 15: 3585-3590.
7. Peloponissios N, Halkic N, Pugnale M, Jornod P, Nordback P, et al. (2003) Hepatic Portal Gas in Adults: Review of the Literature and Presentation of a Consecutive Series of 11 Cases. *Arch Surg* 138: 1367-1370.



Journal of Anesthesia & Clinical Care
Journal of Addiction & Addictive Disorders
Advances in Microbiology Research
Advances in Industrial Biotechnology
Journal of Agronomy & Agricultural Science
Journal of AIDS Clinical Research & STDs
Journal of Alcoholism, Drug Abuse & Substance Dependence
Journal of Allergy Disorders & Therapy
Journal of Alternative, Complementary & Integrative Medicine
Journal of Alzheimer's & Neurodegenerative Diseases
Journal of Angiology & Vascular Surgery
Journal of Animal Research & Veterinary Science
Archives of Zoological Studies
Archives of Urology
Journal of Atmospheric & Earth-Sciences
Journal of Aquaculture & Fisheries
Journal of Biotech Research & Biochemistry
Journal of Brain & Neuroscience Research
Journal of Cancer Biology & Treatment
Journal of Cardiology: Study & Research
Journal of Cell Biology & Cell Metabolism
Journal of Clinical Dermatology & Therapy
Journal of Clinical Immunology & Immunotherapy
Journal of Clinical Studies & Medical Case Reports
Journal of Community Medicine & Public Health Care
Current Trends: Medical & Biological Engineering
Journal of Cytology & Tissue Biology
Journal of Dentistry: Oral Health & Cosmesis
Journal of Diabetes & Metabolic Disorders
Journal of Dairy Research & Technology
Journal of Emergency Medicine Trauma & Surgical Care
Journal of Environmental Science: Current Research
Journal of Food Science & Nutrition
Journal of Forensic, Legal & Investigative Sciences
Journal of Gastroenterology & Hepatology Research
Journal of Gerontology & Geriatric Medicine
Journal of Genetics & Genomic Sciences
Journal of Hematology, Blood Transfusion & Disorders
Journal of Human Endocrinology
Journal of Hospice & Palliative Medical Care
Journal of Internal Medicine & Primary Healthcare
Journal of Infectious & Non Infectious Diseases
Journal of Light & Laser: Current Trends
Journal of Modern Chemical Sciences
Journal of Medicine: Study & Research
Journal of Nanotechnology: Nanomedicine & Nanobiotechnology
Journal of Neonatology & Clinical Pediatrics
Journal of Nephrology & Renal Therapy
Journal of Non Invasive Vascular Investigation
Journal of Nuclear Medicine, Radiology & Radiation Therapy
Journal of Obesity & Weight Loss
Journal of Orthopedic Research & Physiotherapy
Journal of Otolaryngology, Head & Neck Surgery
Journal of Protein Research & Bioinformatics
Journal of Pathology Clinical & Medical Research
Journal of Pharmacology, Pharmaceutics & Pharmacovigilance
Journal of Physical Medicine, Rehabilitation & Disabilities
Journal of Plant Science: Current Research
Journal of Psychiatry, Depression & Anxiety
Journal of Pulmonary Medicine & Respiratory Research
Journal of Practical & Professional Nursing
Journal of Reproductive Medicine, Gynaecology & Obstetrics
Journal of Stem Cells Research, Development & Therapy
Journal of Surgery: Current Trends & Innovations
Journal of Toxicology: Current Research
Journal of Translational Science and Research
Trends in Anatomy & Physiology
Journal of Vaccines Research & Vaccination
Journal of Virology & Antivirals
Archives of Surgery and Surgical Education
Sports Medicine and Injury Care Journal
International Journal of Case Reports and Therapeutic Studies

Submit Your Manuscript: <http://www.heraldopenaccess.us/Online-Submission.php>