

Research Article

Contribution of Three-Dimensional Reconstructions from CT-Scan for Assessing the Factors Associated with Blunt Splenic Injury Severity

Anne-Sophie Studer^{1*}, Cyril JF Kahn¹, Anderson Loundou², Kathia Chaumoitre³, Stéphane Berdah¹, Ronald Denis⁴, Christian Brunet¹ and Thierry Bège¹

¹Department of General and Digestive Surgery, North Hospital, Aix-Marseille University, Marseille, France

²Department of Clinical Research, Unit Help Methodology in Clinical Research, Laboratory of Public Health, Aix-Marseille University, Marseille, France

³Department of Imaging and Interventional Radiology, North Hospital, Aix-Marseille University, Marseille, France

⁴Department of Surgery and Traumatology, Sacré Coeur Hospital, Université de Montréal, Quebec, Canada

Abstract

Purpose

Analysis of influence of anthropomorphometry, splenic variability and crash's circumstances on the severity of splenic injury.

Methods

Seventy-seven patients with blunt splenic trauma had a tomodesitometry at time of admission. Localisation, type, and lesion's severity (AAST classification), were determined. Severe splenic lesion was defined by: Grade 4 or 5, lesion of entire parenchyma, or fracture. Three-dimensional splenic segmentation allowed calculation of volume, orientation (colatitude and azimuth), morphometry, morphology and span of hilar vessels. Anthropometric parameters were:

*Corresponding author: Anne-Sophie Studer, Department of General and Digestive Surgery, North Hospital, Aix-Marseille University, Marseille, France, Tel: +33 0491968170, E-mail: annesophiestuder@yahoo.fr

Citation: Studer A-S, Kahn CJF, Loundou A, Chaumoitre K, Berdah B, et al. (2018) Contribution of Three-Dimensional Reconstructions from CT-Scan for Assessing the Factors Associated with Blunt Splenic Injury Severity. Trends Anat Physiol 1: 004.

Received: January 23, 2018; **Accepted:** February 28, 2018; **Published:** March 10, 2018

Copyright: © 2018 Studer A-S, et al. This is an open-access article distributed under the terms of the Creative Commons Attribution License, which permits unrestricted use, distribution, and reproduction in any medium, provided the original author and source are credited.

Age, gender, BMI, and morphotype. Relationships between spleen, stomach, liver and 10th left rib were detailed.

Results

In univariate analysis, splenic parameters for a severer lesion were: Orientation of hilar side turned towards vertebral column (azimuth, $p=0.05$), spread conformation of hilar vessels ($p=0.10$), and high splenic volume ($p=0.06$). The younger the patient, the more severe was the splenic lesion ($p=0.07$). A full stomach and a left liver overflowing in the left hypochondrium, were associated with low gravity splenic lesion, ($p=0.02$ and $p=0.03$). In multivariable analysis, injured patients whose hilar area was vertically oriented, were more at risk of severe splenic lesion (OR=0.92, 95% CI (0.85-0.99), $p=0.02$). An abdominal-shaped liver was associated with low gravity splenic lesion (OR= 0.13, 95% CI (0.02-0.93), $p=0.04$).

Conclusions

Topographic and morphologic variability of the spleen condition its vulnerability in trauma cases. Using this analysis and the biomechanical behaviour of splenic tissue will allow for the creation of a splenic numerical model, and its integration in the virtual human scientific application of modern traumatology.

Keywords: Anthropometry; Blunt splenic trauma; Morphometry; Splenic modelisation; Splenic variability

Background

Road accidents account for over 80% of abdominal injuries [1] and the spleen remains the most frequently injured abdominal organ during blunt trauma [2]. Because of its rich vascularisation, the spleen is at high risk for haemorrhage and death [2,3]. The management of splenic trauma has changed radically over the last decades, because of accrued knowledge on the risk of sepsis post splenectomy and developments in non-operative management [4,5]. Nowadays, the success rate of non-operative management in trauma teams is up to 80-90% [6], and only haemodynamic unstable patients are operated. Arterial embolization also seems to improve the success of non-operative management [7], but needs further evaluation.

Nevertheless, a failure of non-operative management can occur in almost 10-15% of cases [8]. The severity of the splenic injury, defined by the American Association for the Surgery of Trauma (AAST) [9], is the most accurate predictive factor for failure of non-operative management, both in the early phase but also during the monitoring period.

Although clinical management of blunt splenic trauma is fairly well codified, relatively little is known about the process leading to splenic injury. Only a few studies have explored the biomechanics of the spleen [10-13]. Currently, there is no experimental or numerical model reproducing blunt traumatic splenic injury. Such models could ultimately help to better understand the circumstances, and patients at risk, of severe splenic injury [14]. One explanation for this lack of splenic lesion model could be the high complexity of this type of trauma, and the high variability of the splenic anatomy could be another.

The variability of spleen morphometry (mostly spleen volume) has already been investigated by numerous anatomical and radiological studies [15,16]. Very little is known however on the three-dimensional anatomy of the spleen (morphology, spatial orientation, anatomical relationships).

In a previous work, we described the three-dimensional anatomy of the spleen using a CT-scanner in non traumatized patients [16]. The aim of the present study was to evaluate the three-dimensional splenic anatomy in traumatized patients and the potential effect of this three-dimensional anatomy on injury severity.

Material and Methods

Study population

The data of patients admitted in the regional trauma center of North Hospital of Marseille (France) for blunt abdominal splenic trauma from April 2009 to August 2013 were retrospectively studied. The study was conducted in accordance with the Code of Ethics of the World Medical Association and French law on non-interventional studies using abdominopelvic injected CT-scans. Inclusion criteria were: Age $61 \geq 16$ years, CT-scan at admission, and injury mechanism corresponding to a road accident. Exclusion criteria were: Any other mechanism of splenic injury (i.e., penetrating trauma, fall, crushing...), incomplete files, death at time of admission, patients who had their tomodesitometry in another center, before transfer, or who were operated before the CT scan. The study included 77 patients, in whom splenic and anthropometric measurements were available from tomodesitometry.

Circumstances of the accident

The crash's circumstances were detailed: Type of transport (light vehicle, truck, pedestrian, motorcycle, bicycle), the position in the vehicle, the means of protection (seat belt, airbag, helmet), the characteristics and severity of the crash (extrication outside the vehicle more than 20 minutes, ejection outside the vehicle during crash, tumble crash) and the direction of impact (frontal, lateral right or left and back).

Tomodesitometric analysis of the splenic lesion and splenic three-dimensional reconstruction

Seventy-seven patients had an abdominopelvic tomodesitometry at the portal and arterial phases, in their initial assessment. The splenic lesion was localised as: Superior, inferior, anterior or posterior position, and on the hilar or lateral side (Figure 1).

Lesion severity was graded according to the AAST classification [9]. The type of splenic lesion was detailed as contusion, laceration, subcapsular hematoma, intra-parenchymatous hematoma, fracture or burst fracture. A severe splenic lesion was defined by the presence of one of the following anomalies: AAST grade 4 or 5, lesion of the entire parenchyma, lesion corresponding to a fracture or burst fracture. Segmentation and 3D reconstruction of the spleen were done with Mimics 10.01 software (Materialise Software, Belgium). We also segmented both of the 10th ribs, and the 11th thoracic vertebral body, which served as points of reference for spatial localisation of the spleen (Figure 2) [16].

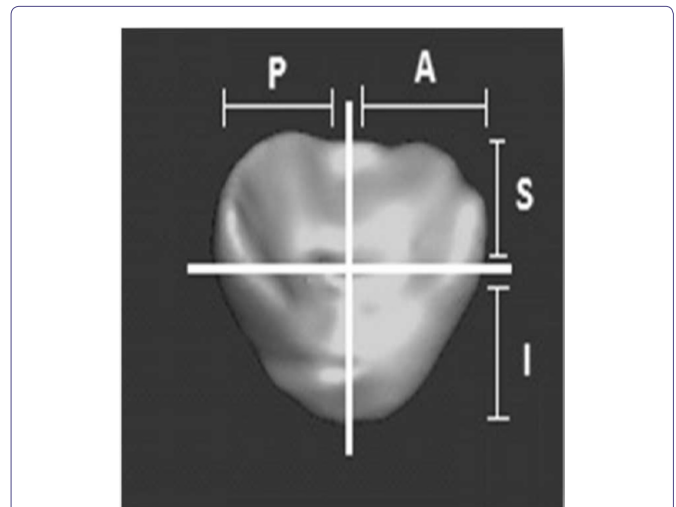


Figure 1: Localisation of the lesion (Hilar surface): (P) Posterior localisation, (A) Anterior localisation, (S) Superior localisation, (I) Inferior localisation.

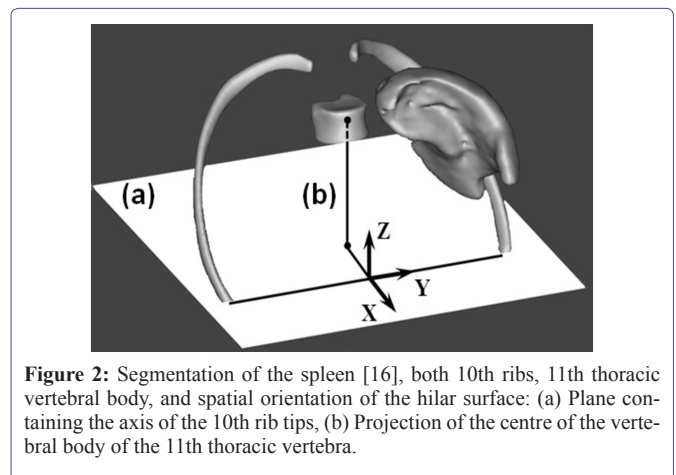


Figure 2: Segmentation of the spleen [16], both 10th ribs, 11th thoracic vertebral body, and spatial orientation of the hilar surface: (a) Plane containing the axis of the 10th rib tips, (b) Projection of the centre of the vertebral body of the 11th thoracic vertebra.

The exact methodology of this three-dimensional reconstruction has been described in a previous publication [16]. This method enabled us to determine splenic volume, morphology, morphometry, orientation, splenic volume boundless rate under the 10th rib, and the span of the hilar vessels. This last parameter was defined as the distance ratio between the highest and the lowest arterial entry points for the total span of the parenchyma, on either side of these entry points. The median was then used to classify the hilum in the grouped type (>0.52) or in the spread type (<0.52). Segmentation enabled us to calculate the spleen's orientation in space, using angle measurements (colatitude and azimuth), and to determine its horizontal axis using the longest axis 91 of the frontal section. It also allowed for an appreciation of the morphometric organisation of the parenchyma, whether it was dorsal or abdominal in shape and which of the three possible morphologies: Coiled, cupped or flat [16].

Anthropometry of the study population

Demographic criteria included age and gender. Anthropometric

data collected at the time of admission provided the nutritional status of each patient, and their Body Mass Index (BMI). Using CT scans, we could measure abdominal circumference, costo-xiphoid angle, abdominal height, and calculate chest depth (the ratio between the greatest antero-posterior distances of a thoracic hemi-field and the transverse diameter of the thoraco abdominal region at the xiphoid floor) [15,17,18]. Stocky or slender morphotypes were determined by at least two of the three criteria (costo-xiphoid angle, abdominal height, and chest depth) [16]. The median for each criteria was chosen as our limit value. Thus, a costo-xiphoid angle greater than 82°, an abdominal height lower than 391 mm and a chest depth greater than 0.62, categorized the patient as stocky. Otherwise, the patient was classified as slender.

Analysis of the relationship between intra-abdominal organs

The relation between the spleen and the liver, the stomach and the 10th left rib, were determined, and the liver's position was described as either ventral or dorsal-shape [15,16] (Coze S. Traumatismes hépatiques fermés: Influence de la morphologie hépatique dans une série de 85 cas explorés par tomodensitométrie. [Medical Thesis-Unpublished results]. Marseille, Aix-Marseille University (2012)).

Having divided the left hypochondrium into four parts, we characterized the development of the left hepatic lobe by the number of quarters occupied. The stomach was described according to its empty or full status. The presence of a fracture of the 10th left rib was investigated.

Statistical Analysis

Statistical analyses were performed by using the Statistical Package for the Social Sciences (SPSS) version 20.0. (IBM SPSS Inc., Chicago, IL, USA). Continuous variables are presented as mean \pm standard deviation or median (min-max) and compared by using the student's t-Test or the Mann-Whitney test. The categorical variables are presented in the form of effective numbers and percentages and compared using the chi-square test or Fisher's exact test. Independent variables, candidate for the univariate analysis, were selected based on a p-value <0.10 or a clinical choice. Multivariable analysis using the logistic regression model was used to identify independent factors affecting the severity of splenic lesions. Adequacy of the data to the logistic model was assessed using the Hosmer-Lemeshow test. Odds ratios are presented with their confidence interval at 95%. The statistical significance for multivariable tests was set at 5% ($p < 0.05$).

Results

Population data and splenic injury

The characteristics of the study population are presented in table 1. Mean age of the population was 32 \pm 15 years old with a majority of men (76.6%). Patients were slender in 63.6% of cases and there were 7 obese patients (9.1%). Trauma victims were in the driver's seat in 61% of cases and 49.4% of impacts were frontal. In 17% of cases, there was no protection system. Splenic injuries, on initial CT-Scan, were classified as low severity AAST grade lesion in 89.7% of patients and severe AAST grade lesion in 10.3% of patients, with lesions mainly located on the hilar side of the spleen (45.5%). Most frequent types of injury were lacerations (31.6%) and fractures (32.6%).

Univariate analysis (Table 2)

There were four splenic parameters for more severe lesions: The hilar side was oriented toward the vertebral column (determined by the azimuth measure, $p=0.05$), a spread conformation of the hilar vessels ($p=0.10$), a recovery of the spleen by the 10th left rib ($p=0.08$) and a high splenic volume ($p=0.06$). Neither the morphometry nor the morphology of the spleen was linked to the severity of the splenic lesion (respectively $p=0.85$ and $p=0.2$) and anthropometric parameters did not seem to influence the seriousness of injury. Obesity did not appear to be an aggravating or protecting argument for splenic trauma ($p=0.62$). Younger patients suffered severe splenic lesions most frequently ($p=0.07$) and gender was not a significant factor ($p=0.44$). As for the circumstances of the accident, none of the situations recorded seemed to influence the severity of the splenic lesion. The use of a seat belt or the airbag setting didn't seem to aggravate or protect from high splenic trauma ($p=0.49$). As to the relationship between intra-abdominal organs, a left liver overflowing in the left hypochondrium and covering the upper part of the spleen was associated with a low severity splenic lesion ($p=0.03$), whereas an empty stomach was associated with more severe splenic lesions ($p=0.02$).

Multivariable analysis

The two parameters that influenced splenic lesions were: Colatitude and hepatic morphometry. Traumatized patients, whose hilar surface was verticalised, were more at risk of a severe splenic lesion (Figure 3) (Colatitude: OR= 0.92, 95% CI: 0.85-0.99, $p=0.02$). Traumatized patients, whose liver was abdominal-shaped, were less at risk of severe splenic lesion (OR= 0.13, 95% CI: 0.02-0.93, $p=0.04$). None of the other parameters (morphometry, morphology, anthropometry or accident circumstances) were associated with the gravity of a splenic trauma.

Discussion

The splenic organ varies widely between individuals in terms of anatomic characteristics, morphology, geometry, orientation in space and vascularisation [16]. In this study, we have shown that some parameters related to the three-dimensional anatomy of the spleen, such as orientation of the splenic vessels, could be associated with the severity of a splenic injury during a road accident.

Splenic lesions may occur in many different circumstances. Therefore, to gather a relatively homogenous population, this study focused on traffic accidents only, but even with this selection parameter, the injury mechanisms involved can be multiple (direct impact, deceleration) and associated. The results in this study show no evidence of aggravating or mitigating circumstances for the conditions in which the accident occurred in severe splenic trauma; even for seatbelt use, which agrees with some studies [19,20]. However, Holbrook et al., have demonstrated the negative role of the seat belt on the liver [21]. The debate continues since studies have shown that the incidence rate of injury to intraabdominal organs was higher for belted passengers [22].

Demographic characteristics		n= 77
Mean age (years)		32±15.2
Gender M/F		59 (76.6%) /18 (23.4%)
Individual Anthropometry		
General morphotype		
Stocky		28 (36.4%)
Slender		49 (63.6%)
Abdominal perimeter (mm)		838.7±121.4
BMI (Kg/Cm2)		
Normal		58 (75.3%)
Overweight		9 (11.7%)
Obesity		5 (6.5%)
Severe obesity		2 (2.6%)
Malnutrition		3 (3.9%)
Accident circumstances		
Pedestrian		3 (3.9%)
Two-wheelers		34 (44.2%)
Truck and light vehicles		40 (51.9%)
Position during the impact		
Driver		47 (61%)
Front passenger		4 (5.2%)
Passenger back left / back right / back middle		4 (5.2%) / 1 (1.3%) / 2 (2.6%)
Direction of the impact		
Lateral right / Lateral left		3 (3.9%) / 8 (10.4%)
Frontal		38 (49.4%)
Back		2 (2.6%)
Gravity of the accident		
Ejection outside the vehicle		11 (14.3)
Extrication outside the vehicle more than 20 minutes		16 (20.8%)
Rolled over		3 (3.9%)
System of protection		
None		13 (16.9%)
Seat belt		20 (26%)
Helmet		25 (32.5%)
Airbag		19 (24.6%)
Morphometric analysis of the spleen and neighbouring organs		
Splenic characteristics		
Splenic volume (cc)		233.2±119.5
Splenic morphometry		
Abdominal-shape		41 (53.3%)
Dorsal-shape		36 (46.7%)
Angle between horizontal and biggest axis of the spleen (°)		50.5±12.6
Splenic morphology		
Flat		13 (16.9%)
Cupped		57 (74%)
Coiled		7 (9.1%)
Percentage of splenic volume under the 10th left rib		
0%		5 (6.5%)
Less than 20%		18 (23.4%)
20 - 50%		30 (38.9%)
More than 50%		24 (31.2%)
Orientation in space		
Colatitude (°)		80±20.7
Azimuth (°)		118.6±29

Conformation of hilar vessels	
Spread	37 (48.1%)
Grouped	40 (51.9%)
Neighbouring organs	
Occupation of the left hypochondrium by the left liver	
01/4	26 (33.8%)
01/2	28 (36.4%)
03/4	15 (19.5%)
04/4	8 (10.3%)
Hepatic morphometry	
Abdominal-shape	47 (61%)
Dorsal-shape	30 (39%)
Fracture of the left 10th rib	
Stomach	
Full	33 (42.9%)
Empty	25 (32.5%)
Analysis of the splenic lesion	
Splenic lesion: AAST grade	
1	31 (40.3%)
2	24 (31.2%)
3	14 (18.2%)
4	8 (10.3%)
5*	0 (0%)
Localisation of the lesion	
Hilar	35 (45.5%)
Lateral	15 (19.5%)
Lateral and hilar	23 (29.8%)
Splenic tip	4 (5.2%)
Type of lesion	
Contusion	2 (2.6%)
Intra-parenchymatous hematoma	12 (15.5%)
Sub-capsular hematoma	10 (13%)
Laceration	27 (35.1%)
Fracture	23 (29.9%)
Burst	3 (3.9%)

Table 1: Table 1: Descriptive parameters of the study population (Quantitative variables are in mean ± 299 standard deviation).

* No grade 5 in the 77 splenic traumas. 18 / 95 splenic trauma had a splenectomy for haemostasis before going through tomodensitometry.

The analysis of clinical or radiological data does not make it possible to understand the process leading to traumatic injury. However, classifying injuries according to their severity highlights the factors associated with their seriousness, which makes it possible to speculate on the role of each factor in the traumatic process. Orientation of the spleen's hilar surface is associated to severe lesions in this study, as its position affects the way the neighbouring organs will fit together and around the splenic parenchyma and the hilum. If the hilar side is turned toward the front of the body, the hilar vessels will get more protection from the parenchyma behind them. A full stomach will also protect the spleen from severe splenic trauma, acting like an airbag inside the abdomen. The left liver overflowing into the left hypochondrium will have the same protective effect, and, like the rib cage, gastric and hepatic tissues will absorb the shock waves. The incidence of 10th left rib fracture is not related to a more severe splenic lesion in our study. This result reaffirms the debate associated

to the rib cage [23]: Is it a protective hammock or a danger for the parenchyma? in this analysis, the younger patients had the most severe injuries, which suggests anatomical avenues for reflection. As people age, the thoraco-abdominal region changes: Morphotype tends to be stocky, costo-xiphoid angle opens, muscle strap loosens, the vertebral column settles down, and this brings about a re-organisation, re orientation of the relationships between intra-abdominal organs. Factoring for different local conditions, might explain that the elderly present less severe splenic lesions. Likewise, our population of young people, essentially male, corresponds to those more exposed to severe injuries, as highlighted by French demographic data [1]. In this study, a status of obesity was not associated with a higher risk of severe splenic lesion. The adipose tissue would protect the splenic parenchyma in a case of direct impact, but cases of existing deceleration in blunt abdominal trauma have not been studied yet. Other studies on trauma in obese patients have reported that complications due to trauma increase morbidity and mortality rates, but not the severity of the original lesion to the internal organs themselves [24-26].

Parameters	Low severity splenic	High severity splenic	p
	Lesion	Lesion	
Mean age (years)	40±16.3	24±6.8	0.07
Gender M/F	52 (75.3%) / 17 (24.7%)	7 (87.5%) / 1 (12.5%)	0.44
Individual Anthropometry			
General morphotype			0.45
Stocky	25 (36.2%)	3 (37.5%)	
Slender	44 (63.8%)	5 (62.5%)	
BMI (Kg/Cm2)			0.57
Normal	58 (84%)	0 (0%)	
Overweight	7 (10.1%)	2 (25%)	
Obesity	4 (5.7%)	1 (12.5%)	
Severe obesity	2 (2.9%)	0 (0%)	
Malnutrition	3 (4.3%)	0 (0%)	
Accident circumstances			
Type of transport			0.2
Pedestrian	2 (2.9%)	1 (12.5%)	
Two-wheelers	31 (44.9%)	3 (37.5%)	
Truck and light vehicles	36 (52.2%)	4 (50%)	
Position during the impact			0.39
Driver	40 (60.6%)	7 (87.5%)	
Front passenger	3 (4.3%)	1 (12.5%)	
Direction of the impact			0.44
Lateral right	2 (2.9%)	5 (62.5%)	
Frontal	33 (47.8%)	2 (25%)	
Unknown	24 (34.8%)	1 (12.5%)	
Gravity of the accident			0.07
Extrication outside the vehicle more than 20 minutes			
Unknown	13 (18.8%)	3 (37.5%)	
System of protection			0.49
None	9 (13%)	4 (50%)	
Seat belt	19 (27.5%)	1 (12.5%)	
Helmet	23 (33.3%)	2 (25%)	
Airbag	18 (26%)	1 (12.5%)	
Splenic characteristics			

Mean Splenic volume (cc)	233±119.7	233±145.1	0.06
Splenic morphometry			0.85
Abdominal-shape	37 (53.6%)	4 (50%)	
Dorsal-shape	32 (46.4%)	4 (50%)	
Splenic morphology			0.2
Flat	10 (14.5%)	3 (37.5%)	
Cupped	52 (75.4%)	5 (62.5%)	
Coiled	7 (10.1%)	0 (0%)	
Percentage of splenic volume under the 10th left rib			0.08
0%	2 (2.9%)	3 (37.5%)	
Less than 20%	16 (23.2%)	2 (25%)	
20-50%	29 (42%)	1 (12.5%)	
More than 50%	22 (31.9%)	2 (25%)	
Orientation in space (Mean)			
Colatitude (°)	93.2±20.4	66.8±24.4	0.19
Azimuth (°)	123,1±28.8	114.1±29.6	0.05
Conformation of hilar vessels			0.11
Spread	32 (46.4%)	5 (62.5%)	
Grouped	37 (63.6%)	3 (37.5%)	
Neighbouring organs			
Occupation of the left hypochondrium by the left liver			0.48
1/4	22 (31.9%)	4 (50%)	
1/2	24 (34.8%)	4 (50%)	
3/4	15 (21.7%)	0 (0%)	
4/4	8 (11.6%)	0 (0%)	
Hepatic morphometry			0.03
Abdominal-shape	46 (66.7%)	1 (12.5%)	
Dorsal-shape	23 (33.3%)	7 (87.5%)	
Fracture of the left 10th rib	7 (10.1%)	0 (0%)	0.35
Stomach			0.02
Full	30 (43.5%)	3 (37.5%)	
Empty	20 (29%)	5 (62.5%)	
Almost empty	19 (27.5%)	0 (0%)	

Table 2: Significant parameters in univariate analysis, associated with a more severe splenic lesion (p<10%).

The main limitation of this study is the low number of patients included in the severe splenic lesion group. This bias results from the study's methodology which requires a spleen CT-scan. Grade 5 hemodynamically unstable patients go directly to the operative room and undergo haemostasis splenectomy, and are therefore impossible to include in this type of analysis.

Conclusions

This work suggests that parameters of intrinsic and extrinsic variability condition the tolerance threshold of the abdominal organs during trauma. These hypotheses require further laboratory study to define the role of each movement and each anatomical structure in terms of shock resistance [10-13]. Such a study could use a numerical 3D model in which the biomechanical properties of each organ are determined by experimental tests [27-30]. This would be of major interest because it allows for wide-scale tests as they are free from the problems inherent in studies using post-mortem human surrogates. Trauma conditions can be infinitely adapted (high or low kinetic

trauma, car or bike accident and so forth), as well as the means of prevention (effects of seat belts, airbags, and so forth). This virtual human could then be used to improve prevention, protection devices, but also as a way to aid clinical decision.

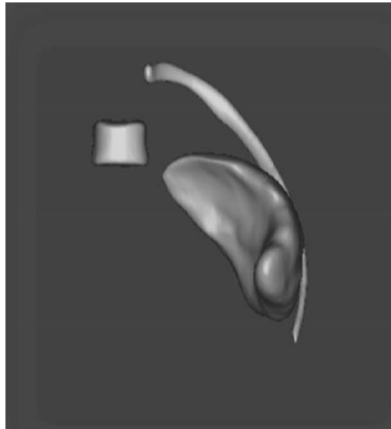


Figure 3: Segmentation of the spleen, the 10th left rib and the 11th thoracic vertebrae (Anterior View). The hilar surface is more verticalized and turns towards the vertebral column.

Compliance with Ethical Standards

Conflict of interest: The authors declare that they have no conflict of interest. For this type of study, formal consent is not required. This article does not contain any studies with animals performed by any of the authors.

Acknowledgment

The authors wish to thank the Laboratory of Applied Biomechanics of Aix-Marseille University, Marseille, France and Kathleen Beaumont for language and writing assistance.

References

1. Observatoire National Interministériel de Sécurité Routière (2012) La sécurité routière en France : Bilan de l'année 2011. Observatoire National Interministériel de Sécurité Routière, La documentation française, France.
2. Cheynel N, Gentil J, Freitz M, Rat P, Ortega Deballon P, et al. (2011) Abdominal and pelvic injuries caused by road traffic accidents: Characteristics and outcomes in a french cohort of 2009 Casualties. *World J Surg* 35: 1621-1625.
3. Helmi I, Hussein A, Ahmed AH (2001) Abdominal trauma due to road traffic accident in Qatar. *Injury* 32: 105-108.
4. Richardson JD (2005) Changes in the management of injuries to the liver and spleen. *J Am Coll Surg* 200: 648-669.
5. Edgren G, Almqvist R, Hartman M, Utter GH (2014) Splenectomy and the risk of sepsis a population-based cohort study. *Ann Surg* 260: 1081-1087.
6. Cirocchi R, Boselli C, Corsi A, Farinella E, Listorti C, et al. (2013) Is non-operative management safe and effective for all splenic blunt trauma? A systematic review. *Crit Care* 17: 185.
7. Liu P, Liu H, Hsieh T, Huang C, Ko SF (2012) Nonsurgical management of delayed splenic rupture after blunt trauma. *J Trauma Acute Care Surg* 72: 1019-1023.
8. Tinkoff G, Esposito TJ, Reed J, Kilgo P, Fildes J, et al. (2008) American association for the surgery of trauma organ injury scale I: Spleen, liver, and kidney, validation based on the national trauma data bank. *J Am Coll Surg* 207: 646-655.
9. Moore EE, Cogbill TH, Jurkovich GJ (1995) Organ injury scaling: Spleen and liver (1994 revision). *J Trauma* 38: 323-324.
10. Stingl J, Báča V, Cech P, Kovanda J, Kovandová H, et al. (2002) Morphology and some biomechanical properties of human liver and spleen. *Surg Radiol Anat* 24: 285-289.
11. Nicolle S, Noguer L, Palierne JF (2012) Shear mechanical properties of the spleen: Experiment and analytical modelling. *J Mecha Behav of Biomed Mater* 9: 130-136.
12. Kemper AR, Santago AC, Stitzel JD, Sparks JL, Duma SM (2012) Biomechanical response of human spleen in tensile loading. *J Biomech* 45: 348-355.
13. Umale S, Deck C, Bourdet N, Dhumane P, Soler L, et al. (2013) Experimental mechanical characterization of abdominal organs: Liver, kidney & spleen. *J Mecha Behav of Biomed Mater* 17: 22-33.
14. Behr M, Arnoux PJ, Serre T, Bidal S, Kang HS, et al. (2003) A human model for road safety: From geometrical acquisition to model validation with radioss. *Comput Methods Biomech Biomed Engin* 6: 263-273.
15. Caix M, Cubertafond P (1978) Etude anatomique de la région thoraco-abdominale considérée en fonction du type morphologique. *Anat Clin* 1: 185-188.
16. Studer AS, Kahn CJF, Bège T, Thollon L, Loundou A, et al. (2015) An anatomic and morphometric analysis of splenic variability using 3D reconstruction and spatial orientation from computed tomography. *Ann Anat* 201: 50-55.
17. Didansky PM (1925) Les divers types de formes et de position des organes du corps humain. In: *Bulletins et mémoires, Société anatomique de Paris, Paris, France.*
18. Dufour, Rigaud, Cabanié, Gouazé (1952) Les types morphologiques humains. In: *Bulletins et mémoires, Société anatomique de Paris, Paris, France.* Pg no: 174-186.
19. Rutledge R, Thomason M, Oller D, Meredith W, Moylan J, et al. (1991) The spectrum of abdominal injuries associated with the use of seat belts. *J Trauma* 31: 825-826.
20. Siegel JH, Mason-Gonzalez S, Dischinger P, Cushing B, Read K, et al. (1993) Safety belt restraints and compartment intrusions in frontal and lateral motor vehicle crashes: Mechanisms of injuries, complications, and acute care costs. *J Trauma* 34: 736-758.
21. Holbrook TL, Hoyt DB, Eastman AB, Sise MJ, Kennedy F, et al. (2007) The impact of safety belt use on liver injuries in motor vehicle crashes: The importance of motor vehicle safety systems. *J Trauma* 63: 300-306.
22. Sharma OP, Oswanski MF, Kaminski BP, Issa NM, Duffy B, et al. (2009) Clinical implications of the seat belt sign in blunt trauma. *Am Surg* 75: 822-827.
23. Park S (2012) Clinical analysis for the correlation of intra-abdominal organ injury in the patients with rib fracture. *Korean J Thorac Cardiovasc Surg* 45: 246-250.
24. Hoffmann M, Lefering R, Gruber-Rathmann M, Rueger JM, Lehmann W (2012) The impact of BMI on polytrauma outcome. *Injury* 43: 184-188.
25. Cramer C, Rueger JM, Hoffmann M (2013) Fat or thin: Does it impact outcomes in polytrauma? *J Trauma* 15: 301-307.
26. Ditillo M, Pandit V, Rhee P, Aziz H, Hadeed S, et al (2014) Morbid obesity predisposes trauma patients to worse outcomes: A national trauma data bank analysis. *J Trauma Acute Care Surg* 76: 176-179.

27. Brunet C, Serre T, Cheynel N, Arnoux PJ, Thollon L, et al. (2004) Les traumatismes virtuels du foie : apport des essais expérimentaux en sollicitation dynamique et de la modélisation numérique. *E-mémoires de l'ANC* 3: 73-82.
28. Bourgoin S, Bège T, Lalonde N, Mancini J, Masson C, et al. (2012) Three dimensional determination of variability in colon anatomy: Applications for numerical modeling of the intestine. *J Surg Res* 178: 172-180.
29. Massalou D, Bège T, Masson C, Bourgoin S, Foti P, et al. (2013) Influence of loading speed on the mechanical properties of the colon. *Comput Methods Biomech Biomed Engin* 16: 189-190.
30. Bège T, Ménard J, Tremblay J, Denis R, Arnoux PJ, et al. (2015) Biomechanical analysis of traumatic mesenteric avulsion. *Med Biol Eng Comput* 53: 187-194.

