

Case Report

Giant Mediastinal Schwannoma: Is a Hybrid Approach the New Mandatory Checkpoint?

Christina Popovic* and Masashi Ura

*Department of Cardiothoracic Surgery, Princess Alexandra Hospital, Brisbane, QLD, Australia***Abstract**

We present the case of a 53 year-old female with a giant mediastinal schwannoma and neovascularisation from the aorta and intercostal arteries. Given her risk of intraoperative bleeding complications, elective preoperative angiography and embolization was performed in order to minimise intraoperative blood loss from the mass and associated vasculature. This resulted in improved operative visibility, as well as faster recovery and freedom from blood transfusion post-operatively. To our knowledge this is the first reported patient with a Schwannoma to undergo pre-operative angiography and planned embolization for the purpose of minimising intraoperative blood loss.

Keywords: Angiography; Embolization; Mediastinum; Schwannoma**Introduction**

Schwannomas are the most common neurogenic tumour of the posterior mediastinum. Although usually benign and incidentally diagnosed, increasing size can cause physiologic compromise. Thus, complete surgical resection is recommended.

It has been well-described in the medical literature, that patients with giant mediastinal schwannomas often present with well-circumscribed, neovascularised masses. Severe bleeding has been reported on presentation as well as intra-operatively [1,2], leading to hypovolemia, cardiac arrest, abandoned procedures, blood transfusions and increased morbidity [3]. With the increasing use of percutaneous angiobolisation interventions, a hybrid approach to haemostasis was planned to minimise complications and improve outcomes.

***Corresponding author:** Christina Popovic, Department of Cardiothoracic Surgery, Princess Alexandra Hospital, 199 Ipswich Road Woolloongabba 4102, Australia, Tel: +61 731762111; E-mail: popovicchristina@gmail.com

Citation: Popovic C, Ura M (2019) Giant Mediastinal Schwannoma: Is a Hybrid Approach the New Mandatory Checkpoint? *Archiv Surg S Educ* 1: 003.

Received: February 11, 2019; **Accepted:** March 05, 2019; **Published:** March 15, 2019

Copyright: © 2019 Popovic C and Ura M. This is an open-access article distributed under the terms of the Creative Commons Attribution License, which permits unrestricted use, distribution, and reproduction in any medium, provided the original author and source are credited.

Case Report

A 53-year-old female presented with new dyspnoea, orthopnoea, increasing peripheral oedema and hypoxia leading to type 2 respiratory failure. This was on a background of progressive dyspnoea for one month. On further history, new mid-thoracic 'electric' pains were reported along with small volume rusty haemoptysis noted the preceding week. She had a known left thoracic Schwannoma diagnosed sixteen years prior on core biopsy. Last surveillance CT three years prior was reported as stable. She was never referred for surgical resection. She had no clinical signs of neurofibromatosis.

A CT Pulmonary Angiogram demonstrated a 100x88x69 millimeter soft tissue mass in the left hemithorax with associated atelectasis and a large pleural effusion. An intercostal catheter subsequently drained over a liter of haemorrhagic fluid, which was negative for malignancy and infection on cytology and microscopy (Figure 1).

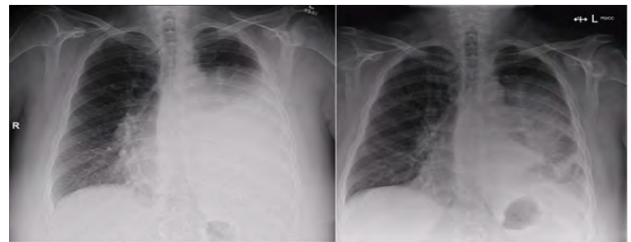


Figure 1: Presentation chest X-ray (left) demonstrating large pleural effusion prior to drainage and subsequent chest X-ray following intercostal catheter insertion.

An MRI Chest demonstrated a heterogenous appearance most likely consistent with ancient change, although malignant transformation was not excluded. Multiple new enhancing mediastinal and retrocrural foci were indicative of further slowly progressive nerve sheath lesions. A repeat biopsy confirmed benign schwannoma.

A dedicated CT angiogram demonstrated multi-level intercostal arterial vascular supply. The mass displaced the left hilar vessels anteriorly with compressive atelectasis of the posterior left upper and lower lobes, and there was concern for inadequate surgical access for haemostasis (Figure 2).

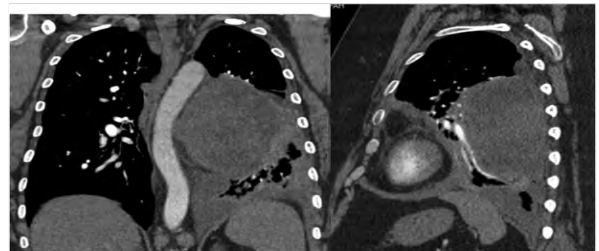


Figure 2: Coronal and sagittal sections of the posterior mediastinal mass, with adjacent atelectasis. CT Angiogram demonstrating mass with deviation of aorta, and vascular supply.

Due to the risk of haemorrhage and difficulty mobilising such a large fixed mass, formal angiography and embolization was requested to coil feeding vessels. This demonstrated arterial supply to the Schwannoma from the left T6 and T7 intercostal arteries, which were then selectively embolised without complication (Figure 3).




Figure 3: (A) Angiography demonstrating intercostal arterial supply to Schwannoma at level T6, (B) Subsequent angiogram following the interval embolisation coil placed in T6 intercostal artery, (C) Angiography of T7 intercostal artery with feeding vessels to Schwannoma, (D) Angiography following angioembolisation of T7 intercostal artery with no demonstrated vascular supply to Schwannoma.

The patient then underwent a left posterolateral thoracotomy and resection. Findings included a large solid, grey, well-encapsulated mass with further nutrient vessels from intercostal arteries and the aorta. Due to the bulky nature of the tumour and adherence to surrounding structures, surrounding vessel ligation and mobilisation was eventually achieved with great difficulty, including tumour debulking and posterior rib dislocation. Two smaller masses were also resected. Exhaustive decortication was then performed for long-term haemorrhagic lung consolidation and compression, with excellent lung re-inflation.

Histopathology confirmed benign Schwannoma. The patient had no post-operative complications and did not require a blood transfusion. She was discharged home after eleven days. Her symptoms resolved and she was recurrence-free on CT surveillance at 12 month follow-up.

Discussion

Mediastinal tumors are the most common cause of a posterior mediastinal mass [4]. They develop from mediastinal peripheral nerves, sympathetic and parasympathetic ganglia, and embryonic neural tube remnants [5].

Only recently has the use of elective pre-operative angiography and embolization been increasingly reported with the more routine use of interventional angiography. Historically, most of these procedures have been to delineate spinal vascular supply by identifying the artery of Adamkiewicz or to investigate potential neuroforaminal involvement, often in conjunction with a neurosurgical consultation and combined approach. It has become common practice to consider spinal angiography if the tumor is located near the site of the Adamkiewicz artery [3].

Bleeding complications have been well-described for giant schwannomas, as incidental findings leading to diagnosis as well as intra-operative complications [1,2]. This has led to VATS conversion to thoracotomy, increased morbidity or abandoned procedures due to blood loss [3,6]. Others also report debulking without complete resection due to poor exposure from ongoing nutrient vessel bleeding [7].

There has been increasing suggestion that a certain subset of patients would benefit from elective pre-operative angioembolization of large mediastinal tumors, however no indications or guidelines are defined. Surgical excision usually confers excellent survival and recurrence is uncommon, however without complete resection of the tumour, risk of recurrence is increased [8]. Therefore, all attempts should be made to achieve complete excision, including hybrid haemostasis.

Conclusion

We present the case of successful elective preoperative angioembolization and subsequent uncomplicated resection of a giant posterior mediastinal mass. We suggest that pre-operative angiography +/- embolization should be considered in patients with a large mediastinal mass where concerns arise for major intraoperative blood loss due to vascular anatomy, difficulties with thoracic access and where completeness of tumour excision may be compromised by these factors.

Funding/Conflicts of Interest

None.

References

- Jang, JY, Kim JS, Choe JW, Kim MK, Jung JW, et al. (2013) A Case of Giant, Benign Schwannoma Associated with Total Lung Collapse by Bloody Effusion. *Tuberc Respir Dis (Seoul)*75: 71-74.
- Kato M, Shiota S, Shiga K, Takagi H, Mori H, et al. (2011) Benign giant mediastinal schwannoma presenting as cardiac tamponade in a woman: a case report. *J Med Case Rep* 5: 61.
- Madariaga ML, Borges LF, Rabinov JD, Chang DC, Lanuti M, et al. (2018) Angiography Before Posterior Mediastinal Tumor Resection: Selection Criteria and Patient Outcomes. *Ann Thorac Surg* 105: 1000-1007.
- Strollo DC, Rosado-de-Christenson ML, Jett JR (1997) Primary mediastinal tumors: Part II. Tumors of the middle and posterior mediastinum. *Chest* 112: 1344-1357.
- Marchevsky AM (1999) Mediastinal tumors of peripheral nervous system origin. *Semin Diagn Pathol* 16: 65-78.
- Ciriaco P, Negri G, Bandiera A, Casiraghi M, Ferla L, et al. (2006) Videothoroscopic Resection of Benign Neurogenic Tumors of the Posterior Mediastinum. *Innovations (Phila)* 1: 332-334.
- Wu Y, Zhang J, Chai Y (2016) Giant mediastinal schwannoma located in the lower right side of the chest. *Nigerian Journal of Clinical Practice* 19: 678-680.
- Quarteya B, Lenertb J, Deb SJ, Henrye LR (2011) Giant posterior mediastinal ancient schwannoma requiring thoracoabdominal resection: A case report and literature review. *World J Oncol* 2: 181-184.



- Journal of Anesthesia & Clinical Care
Journal of Addiction & Addictive Disorders
Advances in Microbiology Research
Advances in Industrial Biotechnology
Journal of Agronomy & Agricultural Science
Journal of AIDS Clinical Research & STDs
Journal of Alcoholism, Drug Abuse & Substance Dependence
Journal of Allergy Disorders & Therapy
Journal of Alternative, Complementary & Integrative Medicine
Journal of Alzheimer's & Neurodegenerative Diseases
Journal of Angiology & Vascular Surgery
Journal of Animal Research & Veterinary Science
Archives of Zoological Studies
Archives of Urology
Journal of Atmospheric & Earth-Sciences
Journal of Aquaculture & Fisheries
Journal of Biotech Research & Biochemistry
Journal of Brain & Neuroscience Research
Journal of Cancer Biology & Treatment
Journal of Cardiology: Study & Research
Journal of Cell Biology & Cell Metabolism
Journal of Clinical Dermatology & Therapy
Journal of Clinical Immunology & Immunotherapy
Journal of Clinical Studies & Medical Case Reports
Journal of Community Medicine & Public Health Care
Current Trends: Medical & Biological Engineering
Journal of Cytology & Tissue Biology
Journal of Dentistry: Oral Health & Cosmesis
Journal of Diabetes & Metabolic Disorders
Journal of Dairy Research & Technology
Journal of Emergency Medicine Trauma & Surgical Care
Journal of Environmental Science: Current Research
Journal of Food Science & Nutrition
Journal of Forensic, Legal & Investigative Sciences
Journal of Gastroenterology & Hepatology Research
Journal of Gerontology & Geriatric Medicine
Journal of Genetics & Genomic Sciences
Journal of Hematology, Blood Transfusion & Disorders
Journal of Human Endocrinology
Journal of Hospice & Palliative Medical Care
Journal of Internal Medicine & Primary Healthcare
Journal of Infectious & Non Infectious Diseases
Journal of Light & Laser: Current Trends
Journal of Modern Chemical Sciences
Journal of Medicine: Study & Research
Journal of Nanotechnology: Nanomedicine & Nanobiotechnology
Journal of Neonatology & Clinical Pediatrics
Journal of Nephrology & Renal Therapy
Journal of Non Invasive Vascular Investigation
Journal of Nuclear Medicine, Radiology & Radiation Therapy
Journal of Obesity & Weight Loss
Journal of Orthopedic Research & Physiotherapy
Journal of Otolaryngology, Head & Neck Surgery
Journal of Protein Research & Bioinformatics
Journal of Pathology Clinical & Medical Research
Journal of Pharmacology, Pharmaceutics & Pharmacovigilance
Journal of Physical Medicine, Rehabilitation & Disabilities
Journal of Plant Science: Current Research
Journal of Psychiatry, Depression & Anxiety
Journal of Pulmonary Medicine & Respiratory Research
Journal of Practical & Professional Nursing
Journal of Reproductive Medicine, Gynaecology & Obstetrics
Journal of Stem Cells Research, Development & Therapy
Journal of Surgery: Current Trends & Innovations
Journal of Toxicology: Current Research
Journal of Translational Science and Research
Trends in Anatomy & Physiology
Journal of Vaccines Research & Vaccination
Journal of Virology & Antivirals
Archives of Surgery and Surgical Education
Sports Medicine and Injury Care Journal
International Journal of Case Reports and Therapeutic Studies

Submit Your Manuscript: <http://www.heraldopenaccess.us/Online-Submission.php>